



A Non-healing Ulcer with Unilateral Facial Palsy

Prasannasrinivas Deshpande^{1*}, Mahima V. Guledgud¹, Karthikeya Patil¹
and Reema Sharon D'souza¹

¹Department of Oral Medicine and Radiology, J.S.S. Dental College and Hospital, J.S.S. University, S.S. Nagar, Mysore-570 015, Karnataka, India.

Authors' contributions

This work was carried out in collaboration between all authors. All authors contributed to diagnostic work up and arrived at the final diagnosis. Authors PD, MVG and KP wrote the draft of the manuscript. Author RSD managed the literature searches. Authors KP, MVG, PD and RSD designed the figures, managed literature searches and contributed to the correction of the draft. Author PD provided the case, the figures and supervised the work. All authors read and approved the final manuscript.

Article Information

DOI: 10.9734/BJMMR/2015/18617

Editor(s):

(1) Hai Ming Wong, The University of Hong Kong, 2/F, Prince Philip Dental Hospital, Hong Kong.

Reviewers:

(1) Anonymous, India.

(2) Anonymous, India.

Complete Peer review History: <http://sciencedomain.org/review-history/9977>

Case Study

Received 1st May 2015
Accepted 10th June 2015
Published 29th June 2015

ABSTRACT

Introduction: Oral cavity is a hub for millions of microorganisms which are non pathogenic, but in immunocompromised states, plethora of diseases emerge which may be the most rarest and fatal. Mucormycosis has emerged as one such disease due to rise in the incidence of immunosuppressive conditions such as uncontrolled diabetes. It manifests as rhinocerebral, gastrointestinal, pulmonary and cutaneous forms.

Presentation of Case: A 53 year old female patient reported with a chief complaint of noticing a painless large ulcer in the palate. There was also history of swelling associated with continuous burning sensation only on the right middle third of face with difficulty in closing right eye, raising right eyebrow, speaking and inability to smile. Bell's sign was positive. She also had recurrent episodes of fever and vomiting. Imaging with CT and MRI showed no bony destruction but a wide spread soft tissue lesion from palate upto the cavernous sinus. Culture and histopathology confirmed mucormycosis.

Discussion: Mucormycosis is the third most common opportunistic fungal infection caused by a saprophytic fungus Mucor. This invasive infection can spread rapidly to intracranium causing various morbidities. Facial nerve palsy is one such rare complication reported in the present case.

*Corresponding author: Email: drprasanna_deshpande@yahoo.com;

Explicit investigations including imaging, serology, histopathology and culture are crucial for appropriate diagnosis. Treatment includes parenteral and oral antifungals.

Conclusion: Mucormycosis is a rare encounter in dental practice especially with initial presenting intraoral symptom. The present paper presents one such rare extensive case of Mucormycosis in a compromised patient with extensive investigations and management.

Keywords: Mucormycosis; mucorales; facial nerve palsy; diabetes.

1. AIMS

Mucormycosis (Zygomycosis, Phycomycosis) [1] is an acute opportunistic fungal infection caused by a saprophytic fungus of class Phycomycetes and genus Mucor [2,3]. These fungi are ubiquitous, surviving on diverse organic material and decaying vegetation.

Of all the invasive fungal infections, it is the third most common following Aspergillosis and Candidiasis species but has been under-reported in India. It manifests as rhinocerebral, gastrointestinal, pulmonary and cutaneous forms affecting males and females equally [3].

Mucormycosis has emerged as an increasingly pathogenic agent due to rise in the incidence of immunosuppressive conditions such as uncontrolled diabetes (particularly with ketoacidosis), [4] malignancies such as leukemia's and lymphoma's, those undergoing cancer chemotherapy or immunosuppressive therapy, renal failure, organ transplant, cirrhosis, burns, protein energy malnutrition and least commonly AIDS. Diabetes mellitus is a common debilitating condition in India and is the most important predisposing factor for this disease [5]. We report a rare and an extensive case of Mucormycosis in a compromised patient involving maxilla, orbit and cavernous sinus.

2. PRESENTATION OF CASE

A 53 year old female patient reported with a chief complaint of noticing a painless large ulcer in the palate since 1 week associated with fever. Patient gave no history of trauma or toothache prior to the onset of the ulcer. There was also history of swelling associated with continuous burning sensation only on the right middle third of face since 5 days. Patient experienced difficulty in closing the right eye, speaking and raising right eyebrows. There was drooling of right corner of mouth and inability to smile. Nasal stuffiness on the right side was also expressed. There was no record of bleeding or pus

discharge as well as malaise, cough or nasal discharge. Patient had dizziness and vomiting on the day of complaint.

She was a known case of diabetes since 8 years and was under medication (Glimepride, metformin) for the same. Her personal history was non contributory.

On general examination, there was gross facial asymmetry with diffuse mild swelling on the right side of the face (Fig. 1) extending from lower orbital margin to lower border of mandible superio-inferiorly and medio-laterally from right lateral wall of nose to tragus of ear with obliteration of nasolabial fold. The swelling was non-tender and firm in consistency. Bell's sign was positive. No nasal deformities were appreciated. Ptosis of right eye was noted. Intra oral examination revealed a solitary well defined ulcer of irregular shape in right hard palate measuring about 5 x 6 cm extending from lateral incisor to first molar. Floor of the ulcer showed a necrotic yellowish black eschar. The border of the ulcer towards the palatal gingiva was erythematous and towards the mid palatine raphe was keratotic and smoothly blending with the surrounding mucosa (Fig. 2). On palpation, the ulcer floor had hard necrotic bone which was non-tender neither mobile.

Based on the history and clinical findings a provisional diagnosis of deep fungal infection, most probably Mucormycosis and differential diagnosis of Aspergillosis, malignant ulcer, tuberculous osteomyelitis, necrotizing sialometaplasia, Wegener's granulomatosis, tuberculous ulcer, syphilitic ulcer and midline lethal granuloma were rendered.

Complete hematological investigations showed normal values except random blood sugar which was found to be 384 mg/dl. Total leukocyte count was 14,540 cells/cumm, blood urea nitrogen was 31 mg/dl and serum creatinine was 1.1 mg/dl. Mantoux and VDRL tests were negative. Patient was seronegative. Moderate amount of ketone (urine ++) were present.

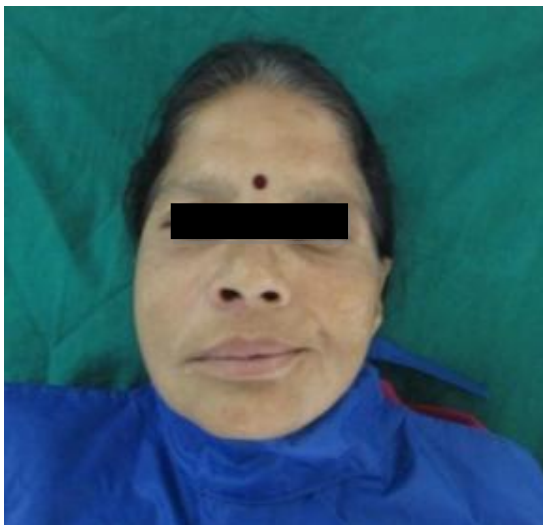

Fig. 1. Photograph showing palsy of right facial muscles

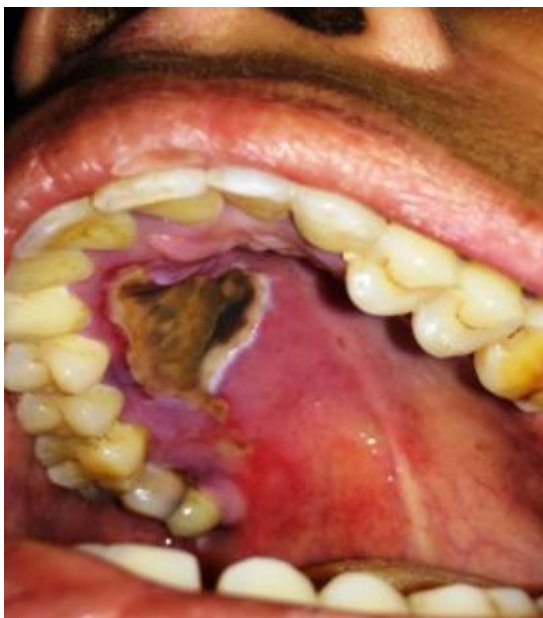

Fig. 2. Well defined ulcer with irregular outline, sloping borders and necrotic eschar over the floor over right side of hard palate

Orthopantomograph and paranasal sinus view was taken. Orthopantomograph showed no gross bony or soft tissue changes. Paranasal sinus view showed haziness in right maxillary sinus. CT of the paranasal sinuses and facial bones showed evidence of mucosal thickening on the right side of Maxillary sinus, Ethmoid sinus and

Sphenoid sinus with occlusion of right osteomeatal complex. Nasal septum was mildly deviated towards right side with hypertrophy of inferior nasal turbinate. There was no evidence of any bony destruction.

MRI of brain with contrast confirmed mucosal thickening in all the above mentioned sinuses. Extension of soft tissue was seen into the right orbit through medial wall of the orbit with its extension into right cavernous sinus in the antero inferior portion, right infratemporal fossa and the right pterygoid fossa. The right lamina cribrosa and fovea ethmoidalis were thinned out and eroded with extradural extension of the soft tissue into the anterior cranial fossa. The soft tissue of the right cheek was edematous and similar altered signal intensity as that of sinuses was noted. No cerebral involvement was noted. CT and MRI features were suggestive of fungal sinusitis (Figs. 3 and 4).

Patient's systemic status was poor and hence, she was hospitalized immediately. She was administered with i.v fluids and insulin therapy was initiated.

Gram staining with K.O.H showed few broad thick walled branching fungal hyphae with no evidence of malignancy in the smear studied. Incisional biopsy revealed fragments composed of stratified squamous epithelium with subepithelial areas of necrosis, vasculitis, hypae and yeast form of mucor and chronic inflammatory cells. Vascular invasion of fungal forms were seen. Periodic Acid Schiff stain also showed hypae and yeast forms of mucor which confirmed the provisional diagnosis (Fig. 4A and 4B). Tissue culture was done and the isolate obtained was insignificant.

Once renal function test and serum electrolytes were normal, local debridement of the area and i.v administration of amphotericin-B 25 mg/day was administered for two weeks. Endoscopic guided medial maxillectomy under GA was then performed. Due to financial constraints patient refused to continue any further treatment and was discharged against the medical advice. Thereafter, Itraconazole 200 mg/day for two weeks and periodic recall every 3 days for local debridement of necrotic tissue in the palate and maxillary sinus was advised. Unfortunately, patient was then lost to follow up.

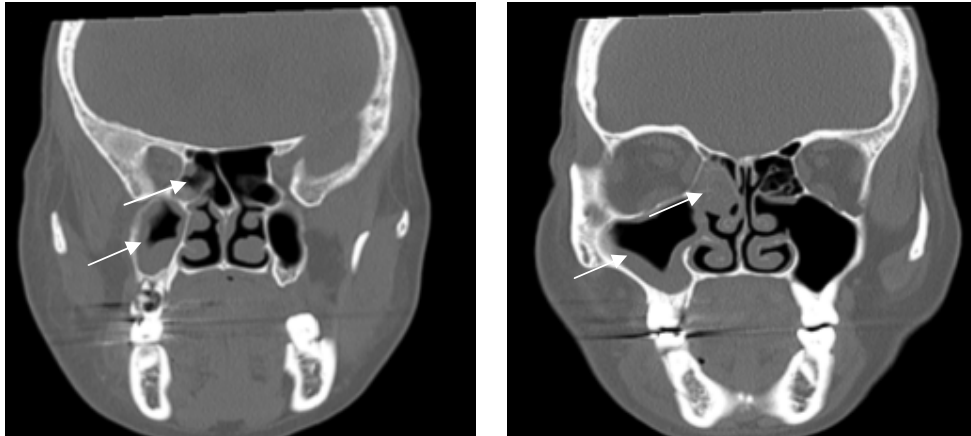


Fig. 3. CT images coronal views showing soft tissue density without significant bony erosion in right maxillary and ethmoid sinus

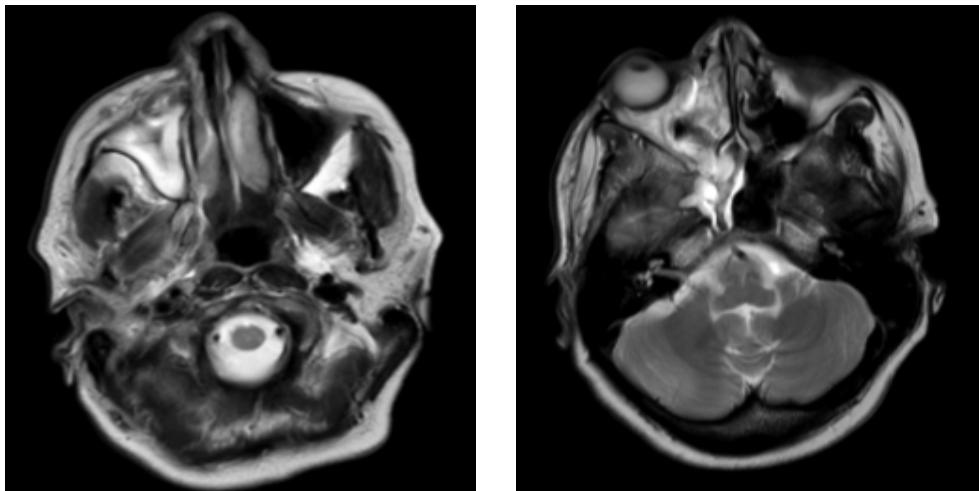


Fig. 4. MRI images showing hyperintense signals on T2 noted in right maxillary, ethmoid and sphenoid sinuses along with extension in medial side of orbit through medial wall and soft tissue extension noted in pterygoid and infratemporal fossa

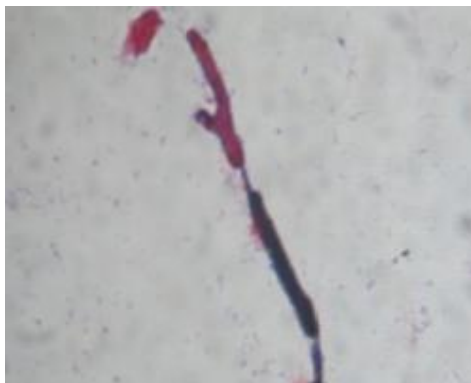


Fig. 4A. KOH: On gram stain broad based thick hyphae were seen

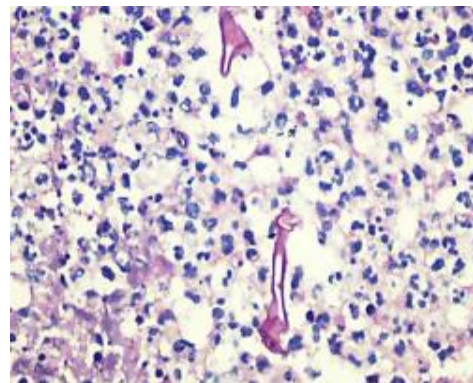


Fig. 4B. PAS X 200 fungal hyphae and inflammatory cells

3. DISCUSSION

Mucormycosis a saprophytic fungus which is usually acquired through airborne spores, ingestion and direct inoculation or contamination of traumatized tissue [6]. Rhizopus is the prime pathogen accounting for 90% of the cases of rhinocerebral mucormycosis [7] and was first described by Paultauf A in 1885 [8].

The fungus is non pathogenic in healthy individuals [1]. Mucorales require neutropenic host, such as those seen in immunocompromised patients with polymorphonuclear leukocyte response, decreased ability to adhere to endothelial walls and decreased phagocytic ability. In addition host also provides increased availability of micronutrients such as iron at low PH as in diabetic ketoacidosis [7]. Hence, Mucormycosis is an aggressive and potentially fatal infection

that occurs in individuals with uncontrolled diabetes.

Fungal hyphae produce a substance called rhizoferrin, which binds to iron avidly in the body. This iron-rhizoferrin complex is then taken up by the fungus and becomes available for vital intracellular processes [8].

Rhino-maxillary form of the disease is a subdivision of rhinocerebral mucormycosis. It usually begins in the nasal mucosa or palate and extends to the paranasal sinuses, spreads either by direct extension from the sinuses through its breach into the bony structures into the orbit or via the angular, lacrimal and ethmoid vessels [7]. It has tendency to disseminate into various organs such as cerebrum or lungs and hence can be fatal [8]. Thrombosis of the internal maxillary artery or descending palatine artery results in necrosis of the maxilla and dead tissues.

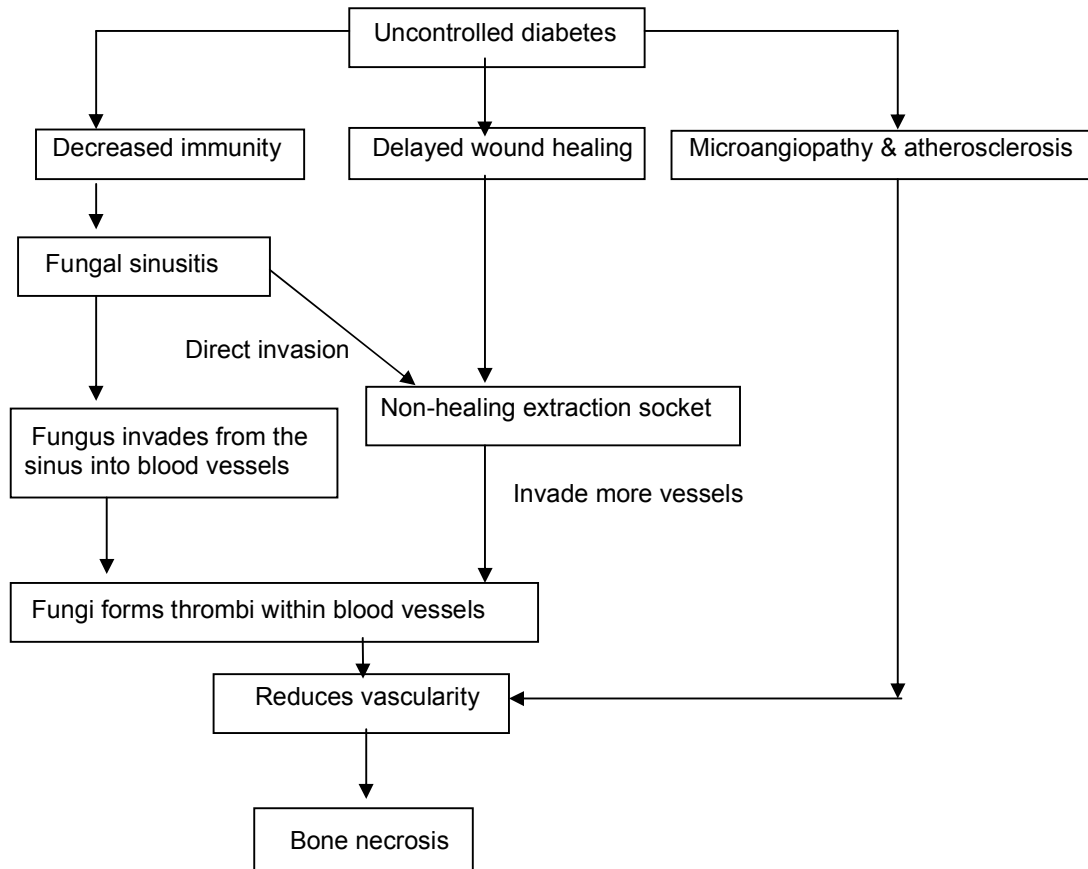


Fig. 5. Pathophysiology of bone necrosis secondary to mucormycotic infection in a diabetic patient [7]

Mucormycosis in early stages exhibits facial cellulitis, nasal discharge, nasal stuffiness, anesthesia, fever, lethargy, headache, localized facial pain, periorbital edema, redness [9], necrotic nasal turbinates and septum and palate that looks like a black eschar [10]. At later stages the fungus progresses either through ophthalmic artery, the superior fissure or the cribriform plate and involves the cranium causing cavernous sinus thrombosis (cerebro-rhino-orbital mucormycosis) ultimately leading to death from cerebral abscess [8].

Orbital involvement may cause loss of function of the second, third, fourth and sixth cranial nerves with proptosis, ptosis, diplopia, orbital pain, central retinal artery occlusion, dilated pupil and loss of vision [8]. In the present case, ptosis indicated involvement of third cranial nerve and signs of bell's palsy due to the extension of the lesion into the infratemporal fossa [11] involving the mandibular division of trigeminal nerve.

Malignant ulcers are chronic ulcers with raised margins, which were not seen in the present case. Necrotizing sialometaplasia is associated with swelling followed by crater like ulceration often associated with pain. However such a presentation wasn't evident in the present case. Midline lethal granuloma characteristically occurs in the midline of oronasal region with area of ulceration, bone necrosis and perforation which was in contrast to present case with ulcer on lateral aspect of hard palate. Wegener's granulomatosis classically presents with necrotizing granulomatous lesions affecting the respiratory tract, glomerulonephritis and disseminated vasculitis [1]. Intra- orally there may be destruction of palate and alveolar bone causing oro-antral fistula. However in the present case no such systemic signs were noted. Serological tests were negative for tuberculosis and syphilis and hence were ruled out.

Histological sections show focal areas of granulomatous inflammation with aseptate hyphae of 6 to 50 μ m in diameter, broad, irregularly branching at 90° having rare septations. [9] The hyphae stains best with Grocott-Gomori-methenamine silver, though periodic acid-Schiff and hematoxylin & eosin stains can also be used [7]. Aspergillosis which has a close clinical resemblance to mucormycosis [7] was ruled out histopathologically.

There are three principles in the management of patient with mucormycosis. Firstly, control of diabetes with diet counselling. Secondly, removal of the necrotic bone, which acts as a nidus of infection and prevents the action of systemically administered antifungal drugs (due to thrombosis of blood vessels). Lastly, with frequent monitoring of blood urea & creatinine levels, amphotericin B has to be administered parenterally as it is the drug of choice in treatment of mucormycotic infection [7]. In the present case all the above modes of management were executed by a co-ordinated team of specialists including an oral diagnostician, oral and maxillofacial surgeon, ophthalmologist, nephrologist, neurosurgeon and ENT surgeon for the present case.

However, mortality rate of mucormycosis has remained more than 40% despite the aggressive surgical and polyene antifungal therapy.

4. CONCLUSION

Mucormycosis is a rapidly progressive, fatal invasive fungal infection in compromised patients, especially diabetes which is on rise since a decade. Such infections are infrequently seen in routine dental practice; hence it may pose a diagnostic and therapeutic dilemma for those who are unfamiliar with its clinical presentation. Associated facial palsy in present case was one such rare complication. Along with such clinical presentations, if mucosal thickening or changes in signal intensities of paranasal sinuses and their surrounding structures are observed on imaging, it should raise high suspicion of fungal infections. When a clinician confronts with such rare potentially fatal disease, awareness of disease manifestations will help early diagnosis and initiation of immediate treatment thus improving the overall morbidity and survival rate of the patient.

CONSENT

All authors declare that written informed consent was obtained from the patient (or other approved parties) for publication of this case report and accompanying images without revealing any personal information.

ETHICAL APPROVAL

It is not applicable.

COMPETING INTERESTS

Authors have declared that no competing interests exist.

REFERENCES

1. Woo SB, Greenberg MS. Ulcerative, Vesicular and Bullous lesions. In *Burket's oral medicine*. 11th edition. Greenberg MS, Glick M, Ship JA. Hamilton: Bc Decker: 2008;41–75.
2. Lin CC, Kuo YT, Lin WC, Chiang C, Liu GC, Chai CY, et al. Rhinocerebral Mucormycosis: How protonmr spectroscopy assisted diagnosis of acute infarction superimposed with cerebritis. *Chin J Radiol*. 2004;29:137-142.
3. Mallis A, Mastronikolis SN, Naxakis SS, Papadas AT. Rhinocerebral Mucormycosis: An update. *European Review for Medical and Pharmacological Sciences*. 2010;14:987-992.
4. Rumboldt Z, Castillo M. Indolent intracranial mucormycosis: Case report. *American Journal of Neuroradiology*. 2002; 23:932–934.
5. Ghafur A, Shareek PS, Nambi P. Senthur, Vidyalakshmi PR, Ramasubramanian V, Ashok Parameswaran, et al. Mucormycosis in patients without Cancer: A case series from a tertiary care hospital in South India. *Journal of the Association of Physicians of India*. 2013;61:305–308.
6. Reddy S. Sujatha, Rakesh N, Jatti Deepa, Lanjekar Ashish, Bijjal Shridevi. Rhino Cerebral Mucormycosis. A report of two cases and review of literature. *J Clin Exp Dent*. 2011;3(3):256-60.
7. Auluck A. Maxillary necrosis by Mucormycosis. A case report and literature review. *Med Oral Patol Oral Cir Bucal*. 2007;12:360 - 4.
8. SdMathebula. Case report: Rhino - orbital Mucormycosis. *S Afr Optom*. 2006;65(2): 78–81.
9. Khattab T, Atra A, Felimban S, Kamal H, Osoba A. Mucormycosis in children with acute lymphoblastic leukemia: report of 5 cases. *Cancer Therapy*. 2008;6:71-76.
10. Branscom R. An overview of mucormycosis. *Laboratorymedicine*. 2002; 33(6):455–457.
11. Meas T, Mouly S, Kania R, Herve D, Herman P, Kevorkian JP, et al. Zygomycosis: An uncommon cause for peripheral facial palsy in diabetes. *Diabetes & Metabolism*. 2007;33:227–229.

© 2015 Deshpande et al.; This is an Open Access article distributed under the terms of the Creative Commons Attribution License (<http://creativecommons.org/licenses/by/4.0>), which permits unrestricted use, distribution, and reproduction in any medium, provided the original work is properly cited.

Peer-review history:

The peer review history for this paper can be accessed here:
<http://sciencedomain.org/review-history/9977>