



Physiotherapeutic Approach for Osteochondroma of 4th And 5th Ribs - A Case Report

Shruti Bhoge^a, Pratik Phansopkar^{a*} and Neha Chitale^a

^a *Department of Musculoskeletal Physiotherapy, Ravi Nair College of Physiotherapy, Datta Meghe
Institute of Medical Sciences, Sawangi, Wardha, India.*

Authors' contributions

This work was carried out in collaboration among all authors. All authors read and approved the final manuscript.

Article Information

DOI: 10.9734/JPRI/2021/v33i50A33410

Editor(s):

(1) Dr. Asmaa Fathi Moustafa Hamouda, Jazan University, Saudi Arabia.

Reviewers:

(1) Amer H. Khan, Universiti Sains, Malaysia.

(2) S. Bindhu, Yenepoya University, India.

Complete Peer review History: <https://www.sdiarticle4.com/review-history/76790>

Case Study

Received 01 September 2021

Accepted 09 November 2021

Published 17 November 2021

ABSTRACT

The most frequent benign bone tumor is osteochondroma, which account for 45 percent of all benign bone tumours. Although not a real neoplasm, osteochondroma (exostosis) is the most common lesion and is often classed as a tumour. The majority of them develop in the metaphyseal region of long bones like the femur and tibia. A 21-year-old female presented to the orthopedic OPD with complaints of pain and swelling over dorsal spine since 2 years with left upper limb radiculopathy since 1 month. Pain was insidious in onset which started 1 month back and it aggravated ever since. On inspection swelling present over paraspinal region of approximately 5cm in length and 4cm in width. On palpation swelling was not adherent to skin, immobile and firm in consistency. Osteochondroma represent the most common bone tumor accounting for 20 to 50% of all benign osseous tumors. In osteochondroma maintaining mobility is important for activities of daily living and to maintain the quality of life. Physiotherapy plays a significant role in maintaining the mobility and improving the quality of life.

Keywords: Ribs; osteochondroma; case report; physiotherapy; excision of osteochondroma.

1. INTRODUCTION

The most frequent benign bone tumor is osteochondroma, which account for 45 percent of all benign bone tumours [1]. Although not a real neoplasm, osteochondroma (exostosis) is the most common lesion and is often classed as a tumour [2]. The majority of them develop in the metaphyseal region of long bones like the femur and tibia [3]. Flat bones and the spine can also develop osteochondroma. A primary chest wall tumour called osteochondroma of the rib is a rare condition. Only 1.5 percent of all osteochondroma are costal osteochondroma. A rib deformity or enlargement with calcification of the cartilaginous cap is the most common appearance. Osteochondroma are most common in children and adolescents, with only a few cases in the elderly. The great majority of these tumours are nonhereditary and appear as a single lesion [4]. Hereditary multiple osteochondroma (HMOs), a condition that is inherited in an autosomal dominant way, account for about 15% of all osteochondroma. Malignant transformation of a single osteochondroma occurs in 1-2 percent of patients, while it occurs in 1 percent to 25 percent of patients with HMO syndrome [5].

Because osteochondroma is frequently asymptomatic, the only clinical symptom is a painless, slow-growing lump on the affected bone. Mechanical irritation of soft tissues, fracture, peripheral nerve or spinal cord compression, damage to blood vessels, internal injury or malignant transformation can all cause symptoms. Osteochondroma are either pediculated or sessile, with a significant diameter of 1 to 2 cm with a thin cartilaginous cap. Osteochondroma occur solely in endochondral ossified bones and are thought to be caused by the lateral section of the growth plate being displaced, which subsequently spreads out from the surrounding joint diagonally to the long axis of the bone [6]. We report the case of a 21-year-old woman who complained of pain over dorsal spine and left upper limb radiculopathy due to osteochondroma of the fourth and fifth left ribs. The appropriate indication for surgery as well as the possible complications are discussed.

2. PATIENT INFORMATION

A 21-year-old female presented to the orthopedic OPD with complaints of pain and swelling over dorsal spine since 2 years with left upper limb

radiculopathy since 1 month. Pain was insidious in onset which started 1 month back and it aggravated ever since. Pain is then associated with tingling and numbness in left upper limb. Swelling had increased gradually over two years with tenderness since past 4 months. The patient's BMI was 22.22. She was right-handed. There was no history of trauma. There was no history of sudden weight lost, fever or any other constitutional symptoms. Patient had taken analgesics for the complaints prescribed by private practitioners. Patient had no significant past history. There was no significant family history.

3. CLINICAL FINDINGS

After obtaining consent from the patient, she was examined. On inspection swelling present over paraspinal region of approximately 5cm in length and 4cm in width. On palpation swelling was not adherent to skin, immobile and firm in consistency. Tenderness was present over swelling. There was spasm of paraspinal muscle. HRCT Thorax showed irregular heterogenous bone density lesion in 4th- 5th intercostal space seen arising from neck of 4th and 5th rib. USG suggested calcified mass in paraspinal region. Fine needle aspiration cytology from swelling suggested chondrocytes admixed with fat cells and muscle fibres.

Table 1. Rom assessment of joint on first day of rehabilitation

Action	Active rom	Passive rom
Shoulder flexion	0-70	0-110
Shoulder abduction	0-50	0-90

4. THERAPEUTIC INTERVENTION

4.1 Phase 1 (0- 4 Weeks)

The primary physiotherapy goal was to maintain mobility, reduce tingling and numbness.

To maintain the mobility of joint, active upper limb range of motion exercises were performed including shoulder flexion, extension, abduction, adduction initially the exercises were performed in gravity eliminated plan progressed to g=antigravity plan 10 repetitions were performed 3 times a day. Chest expansion exercises including thoracic expansion exercises were given in which the patient keeps his/her hand in a crossed way where right hand holds left shoulder

and left hand holds right shoulder and the patient is asked to deep breath it is repeated 07 times in one set and 3 set per day. Transcutaneous electrical nerve stimulation for 7 minutes in sweep pattern.

4.2 Phase 2 (5 to 8 Weeks)

In second phase the goal is to maintain the mobility and increase the strength and cardiovascular endurance.

To increase the strength of upper limb resistance band exercises were given .Initially the exercises were started with yellow resistance band

progressed to red resistance band exercises including shoulder flexion, extension, abduction, adduction were given. For cardiovascular endurance light aerobic exercises were given like spot marching, step ups were given. Cycling for 10 minutes with minimum resistance and walking for 10 minutes was given.

Table 2. ROM assessment of joint on day of rehabilitation

Action	Active Rom	Passive Rom
Shoulder flexion	0-160	0-140
Shoulder abduction	0-160	0-150

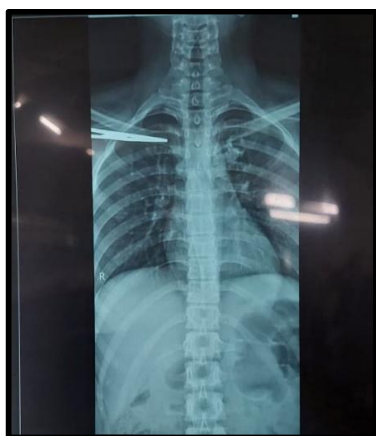

Fig. 1. X-ray of chest (A-P view)

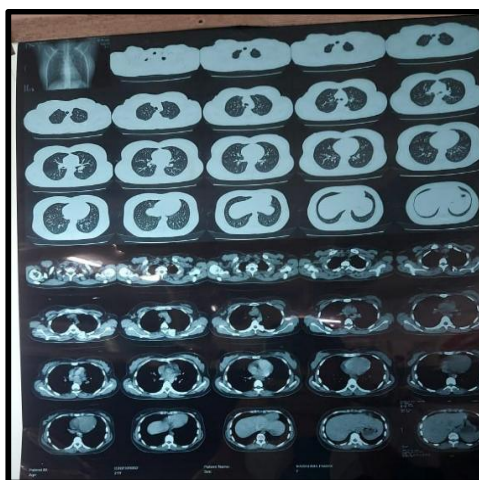


Fig. 2. HRCT

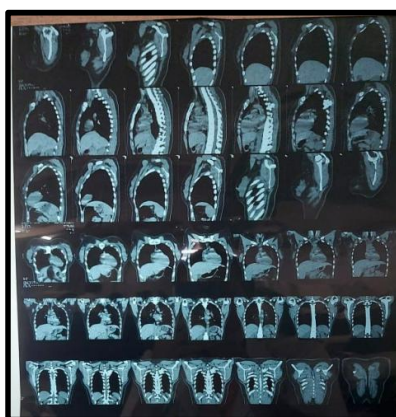


Fig. 3. HRCT thorax

Fig. 1. Shows X ray of chest in antero posterior view shows haziness in the 4th and 5th rib region and the sternocostal area.

Figs. 2 and 3. Shows HRCT of the thorax in anteroposterior and lateral view respectively. Abnormal mass can be seen in both Figs. 2 and 3 which is a finding of osteochondroma

5. DISCUSSION

In this case we present a 21 year old female with osteochondroma of ribs. The primary goal of physiotherapy was to maintain the mobility and to increase the strength and cardiovascular endurance of the patient. The physiotherapy treatment plan included mobility exercises, strengthening exercises with resistance band and aerobic exercises for endurance [7].

Osteochondroma represent the most common bone tumor accounting for 20 to 50% of all benign osseous tumors. Complications associated with osteochondroma are common, including osseous deformities, fracture, and bursa formation with or without bursitis, vascular compromise, neurologic symptoms, and malignant transformation. Mobility is reduced because of the tumor and a role of physiotherapist comes there itself. In this case the osteochondroma is of ribs so, the lung functions are affected as well [8,9]. The goal includes maintaining the lung compliance Costal osteochondroma is a rare but important condition to recognize due to its complications, such as reduced range of movement, pain, cosmetic abnormalities and bursitis. Costal osteochondroma tend to grow into the chest cavity and such lesions are rarely exophytic [10].

6. CONCLUSIONS

Osteochondroma is a common bone tumor which leads to decreased mobility and complications like deformities fractures and many more. In osteochondroma maintaining mobility is important for activities of daily living and to maintain the quality of life. Physiotherapy plays a significant role in maintaining the mobility and improving the quality of life.

CONSENT

The procedure was explained to the patient in patient's language. Informed consent was obtained from the patient.

ETHICAL APPROVAL

It is not applicable.

COMPETING INTERESTS

Authors have declared that no competing interests exist.

REFERENCES

1. Khosla A, Parry RL. Costal osteochondroma causing pneumothorax in an adolescent: a case report and review of the literature. *J Pediatr Surg.* 2010 Nov;45(11):2250–3.
2. Kikuchi R, Mino N, Matsukura T, Hirai T. Resected osteochondroma of the rib in an elderly patient. *Gen Thorac Cardiovasc Surg.* 2010 Nov;58(11):588–91.
3. Bawiskar D, Dhote S, Phansopkar P. Early physical rehabilitation post-surgery in a complex type 5 Schatzker Tibial plateau fracture improves functional outcomes: A case report. 2020;8.
4. Kitsoulis P, Galani V, Stefanaki K, Paraskevas G, Karatzias G, Agnantis NJ, et al. Osteochondromas: review of the clinical, radiological and pathological features. *Vivo Athens Greece.* 2008 Oct;22(5):633–46.
5. Lee C, Huang T, Peng K, Lee MS, Hsu RW, Shen W. Variability of distal femoral valgus resection angle in patients with end-stage osteoarthritis and Genu Varum Deformity: Radiographic Study in An Ethnic Asian Population. 2015;38(4):6.
6. Siroya V, Fernandes L, Wadhokar OC. A pioneering physiotherapeutic approach to the treatment of a covid affected patient – a case report. *J Pharm Res Int.* 2021 Jun 11;17–24.
7. Jachak SP, Phansopkar PA, Naqvi WM, Kumar K. COVID-19, telerehabilitation, pandemic, physiotherapy, health care, economy. *Gt Awak - Telerehabilitation Physiother Pandemic Impact COVID-19 [Internet].* 2020 Sep 11 [cited 2021 Feb 17];(19355). Available: https://www.jemds.com/latest-articles.php?at_id=19355
8. Varani K, Vincenzi F, Pasquini S, Blo I, Salati S, Cadossi M, et al. Pulsed electromagnetic field stimulation in osteogenesis and chondrogenesis: Signaling pathways and therapeutic implications. *Int J Mol Sci.* 2021 Jan 15;22(2):E809.
9. Shah PA, Nemade SV, Naqvi WM. Advance Physiotherapeutic Rehabilitation Approach for Hand Functions in a Giant Cell Tumour Patient- A Case Report on Palliative Physiotherapy. 2020 May [cited 2021 Feb 17];

- Available:<https://imsear.searo.who.int/jspui/handle/123456789/214931>
10. Joshi M. Early Pulmonary rehabilitation approach towards complicated case of acute respiratory failure: enhancing quality of life. J Med Pharm Allied Sci. 2021 Jul 15;10(3):2809–12.

© 2021 Bhoge et al.; This is an Open Access article distributed under the terms of the Creative Commons Attribution License (<http://creativecommons.org/licenses/by/4.0>), which permits unrestricted use, distribution, and reproduction in any medium, provided the original work is properly cited.

Peer-review history:
The peer review history for this paper can be accessed here:
<https://www.sdiarticle4.com/review-history/76790>