



## **Functional and Esthetic Rehabilitation of a Child with Early Childhood Caries: a Case Report**

**Niharika Gahlod<sup>a\*</sup>, Arun Sajjanar<sup>a†</sup>, Suryakant Kumar<sup>a‡</sup>, Milind Wasnik<sup>a#</sup>  
and Sneha Khekade<sup>a#</sup>**

<sup>a</sup> Department of Pedodontics and Preventive Dentistry, Swargiya Dadasaheb Kalmegh Smruti Dental College and Hospital, Wanadongri, Nagpur, Maharashtra, India.

### **Authors' contributions**

*This work was carried out in collaboration among all authors. All authors read and approved the final manuscript.*

### **Article Information**

DOI: 10.9734/JPRI/2021/v33i50A33415

#### Editor(s):

(1) Dr. Mohamed Fawzy Ramadan Hassaniien, Zagazig University, Egypt.

#### Reviewers:

(1) M. S. Beena, Kerala University of Health Sciences, India.

(2) Abhishek Gupta, Tribhuvan University, Nepal.

Complete Peer review History: <https://www.sdiarticle4.com/review-history/76443>

**Case Study**

**Received 05 September 2021**

**Accepted 11 November 2021**

**Published 17 November 2021**

### **ABSTRACT**

Early Childhood Caries (ECC) can be defined as the presence of one or more carious lesions, may or may not be cavitated, and missing teeth due to caries in children up to five years of age. It is multifactorial involving the presence of bacterial plaque, poor oral hygiene, frequency and time of consumption of beverages containing sugar. It has several deleterious effects like it can damage speech, swallowing, feeding, development, esthetics and self-esteem of the child. Therefore, complete oral rehabilitation in such patients is utmost important for their normal growth and development. The current case report involves the oral rehabilitation using different treatment options.

**Keywords:** Customized composite post; early childhood caries; oral rehabilitation; pulpectomy; stainless steel crowns.

<sup>#</sup> Senior Lecturer

<sup>†</sup> Professor & HOD

<sup>‡</sup> Reader

\*Corresponding author: E-mail: [niharika.gahlod@gmail.com](mailto:niharika.gahlod@gmail.com), [niharika.gahlod@sdk-dentalcollege.edu.in](mailto:niharika.gahlod@sdk-dentalcollege.edu.in);

## 1. INTRODUCTION

Early Childhood Caries (ECC) has been an emerging trouble in children up to five years of age. The aetiological factors of ECC are multiple and project the interactions between social, behavioral and microbiological factors [1]. Sugar-rich food and added sugar have received much attention among dietary risk factors for the development of dental caries in children.[2] It has several deleterious effects like it can damage speech, swallowing, feeding, development, esthetics and self-esteem of the child. Habits of unrestricted use of baby bottle, mainly with sugar content during night, are associated with ECC. The parents find difficulty in performing oral hygiene of the child and maintenance of food remnants during longer periods, mainly during sleepiness, also contributes for the establishment of the disease [3]. In addition, the restorative material is influenced by the site and extent of decay, also the cooperative ability of the child. [4] The oral rehabilitation of this case was based on the patient's age, cooperation during procedures and clinical findings.

## 2. CASE REPORT

A 4 and a half years old patient visited to the department with chief complaint of multiple decayed teeth in upper and lower region of jaw. Patient had pain in lower left back region of jaw since 8 days which was aggravating during night and relieved on taking medication. There was no relevant history of any major illness, allergies, hospitalization and blood transfusion reported by parents. The child has first time visited in the dental office. The oral hygiene was maintained by the mother as per co operation of the child. On examination it was found that the child has complete set of deciduous dentition with multiple carious lesions (Fig. no.1 and Fig. no.2).

Grossly decayed teeth were seen in maxillary arch involving central incisors, lateral incisors and first molars. Pit and fissure caries with maxillary second molars (Fig. no.1). Frontal view reveals the presence of sinus with respect to upper right central incisors (Fig. no.3). Mandibular arch shows presence of deep occlusal caries with right and left first and second molars (Fig. no.2).

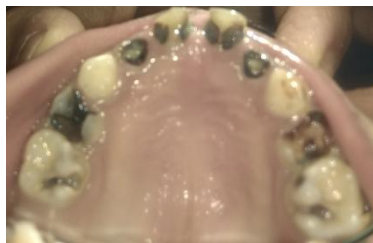

Fig. 1. Maxillary arch

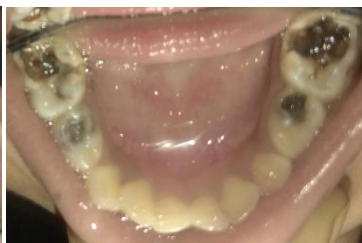

Fig. 2. Mandibular arch

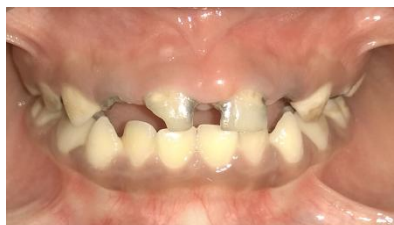

Fig. 3. Frontal view



Fig. 4. IOPA with 51,52,61,62



Fig. 5. IOPA with 74,75

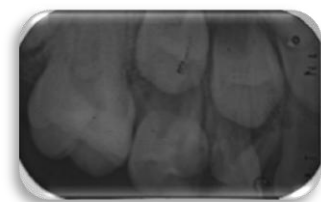

Fig. 6. IOPA with 64,65

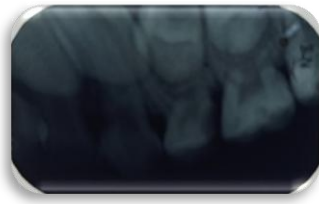

Fig. 7. IOPA with 54,55

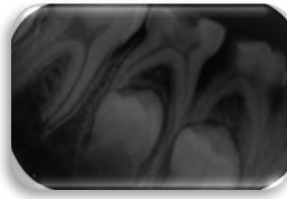


Fig. 8. IOPA with 84,85

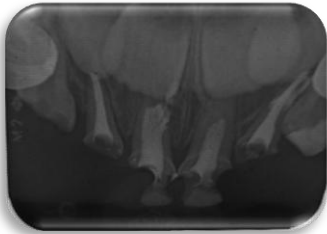


Fig. 9. Pulpectomy with 51,52,61,62

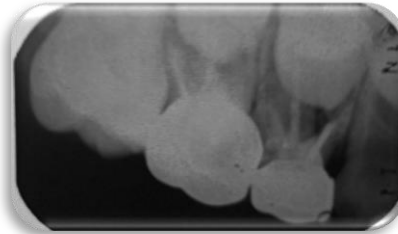


Fig. 10. Pulpectomy with 54,55 & stainless steel crown

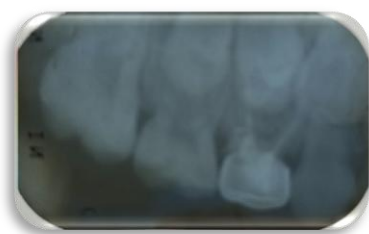

Fig. 11. Pulpectomy with 64 & stainless steel crown

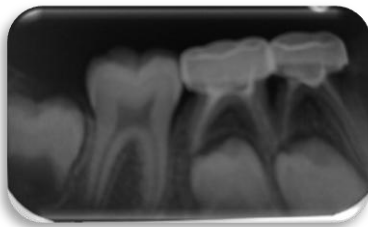


Fig. 12. Pulpectomy with 74,75 & stainless steel crown

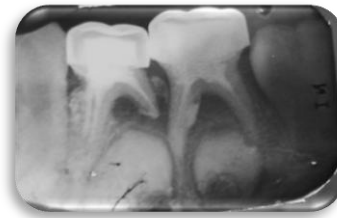


Fig. 13. Pulpectomy with 84,85 & stainless steel crown

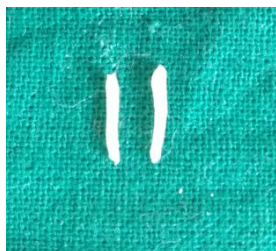

Fig. 14. Custom fabricated composite posts

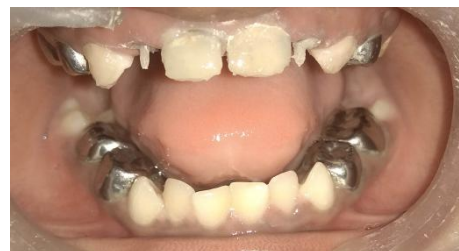

Fig. 15. Composite posts placed with 52,62

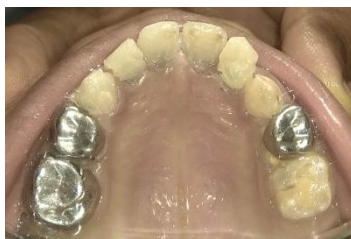

Fig. 16. Post operative view of maxillary arch showing stainless steel crowns in place

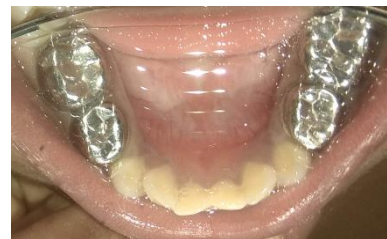
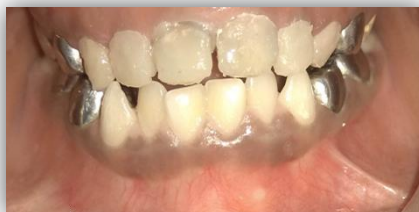
Fig. 17. Post operative view of mandibular arch showing stainless steel crowns in place



**Fig. 18. Post operative frontal view**

On radiographic examination, it was observed that the anterior teeth were mutilated and caries approached upto pulp. Upper right first molar shows radiolucency on distal aspect of crown involving enamel dentine and pulp suggestive of pulpal pathology. Upper left first molar shows mutilated coronal portion where radiolucency has involved pulp suggestive of chronic lesion and second molar shows radiolucency extending upto the pulp chamber from enamel suggestive of pulpal pathology. Lower left first molar shows radiolucency on distal aspect of the crown extending upto the pulp chamber whereas second molar shows radiolucency on the occlusal aspect extending upto the mesial pulp horn suggestive of pulpal involvement. Lower right shows radiolucency on distal aspect of the crown extending upto the pulp chamber whereas second molar shows radiolucency on the occlusal aspect extending upto the pulp chamber suggestive of pulpal pathology.

As per the chief complaint of the patient treatment was initiated with lower left back region of jaw. Pulpectomy was planned with 51,52,61,62, 54, 55, 64, 74,75,84,85. As the crown portion was severely mutilated with 52,62 a custom fabricated composite post was placed followed by the strip crown. Composite post was fabricated using the packable composite resin. A small amount of packable composite resin was rolled between two glass slabs to attain a thickness of rice grain. It was luted using Type I Glass ionomer cement inside the canal. Coronal portion of 51, 61 was built up using composite resin. Stainless steel crowns were given with 54,55,64,74,75,84,85. Patient was advised for the strict modification in diet and oral hygiene maintenance. Patient was asked to be on follow up after every 3 months.

### 3. DISCUSSION

Full mouth rehabilitation of a child with Early childhood caries is challenging for pediatric dentist. [5] Early childhood caries initiates with a

white band of decalcification along the gingival line and occlusal pit and fissure area. Bottle feeding during night is the main culprit for this. Maternal knowledge of oral hygiene practices plays a vital role in prevention of this disease. Early decay of anterior primary teeth results in the development of parafunctional habits such as tongue interposition and speech problems, aesthetic-functional problems due to malocclusion and space loss, and psychological problems which may interfere in the overall personality and behavioural development of the child [1].

ECC can be prevented by maintaining adequate oral hygiene and dietary practices, using agents such as fluoridated toothpaste and visiting dentist after every six months for early detection of carious lesions. Strip crowns provide excellent esthetics, but require exact cementation procedures for retention. According to Waggoner (1994), if caries are present on multiple surfaces of a tooth and the incisal edges are involved along with presence of cervical decalcification requires pulpal therapy [6].

The management of patients with ECC at the tender age is a difficult task as children are very anxious about the dental treatment. [6]. This directly or indirectly affects the child's behaviour. In this case report, the child was very cooperative which help us in getting good results in the treatment.

As the oral health constitutes an integral part of overall general health, ECC if left untreated can lead to far reaching health issues [7]. Preserving the natural tooth is the best way to aid in normal growth and development of the child. There are lot of resources available for the treatment to provide the patient in the best possible way [8-10]. Along with these dental benefits, it also contributes towards the improvement of general and psychological wellbeing of the child [11-12].

#### 4. CONCLUSION

The current case describes the conservative functional and esthetic rehabilitation of the child suffering from early childhood caries. The anterior teeth were severely mutilated and molars had deep caries. The combination of customized post using composite resin and strip crown gave excellent esthetic results. Thus, it is important to detect this in early age and treat. Other factors like diet, oral hygiene maintenance factors must be followed strictly. Continuous follow up results in prevention of such diseases.

#### CONSENT AND ETHICAL APPROVAL

As per international standard or university standard guideline patient's consent and ethical approval has been collected and preserved by the authors.

#### COMPETING INTERESTS

Authors have declared that no competing interests exist.

#### REFERENCES

1. Gabriela Maltz Goldenfum, Sofia Conte Dallagnol, Jonas de Almeida Rodrigues. Early Childhood Caries: A Case Report of an Extensive Rehabilitation. Early Childhood Caries: A Case Report of an Extensive Rehabilitation.
2. Bencze Z, Mahrouseh N, Andrade CAS, Kovács N, Varga O. The Burden of Early Childhood Caries in Children under 5 Years Old in the European Union and Associated Risk Factors: An Ecological Study. *Nutrients* 2021;13:455.
3. Fausto Medeiros Mendes, Monique Saveriano de Benedetto, Cristina Giovannetti del Conde Zardetto, Marcia Turolla Wanderley, Maria Salete Nahás Pires Corra. Resin composite restoration in primary anterior teeth using short-post technique and strip crowns: A case report. *Quintessence International*. 2004;35(9),
4. Megha Jain. Early childhood caries features etiology and management. *International journal of scientific research*. 2020;9(5).
5. Ritika Kriplani, Rakesh Bahadure, Nilima Thosar. Full Mouth Rehabilitation of Early Childhood Caries: A Case Report, *Journal of Datta Meghe Institute of Medical Sciences University* · March 2012;7(1).
6. Milind Atulkar, Milind Wasnik, Suryakant Kumar, Arun Kumar Sajjanar. Dental rehabilitation of early childhood caries: A case report. 2017;2(1):18-22.
7. Pinky Goswami. Early Childhood Caries- A Review of its Etiology, Classification, Consequences, Prevention and Management. *J. Evolution Med. Dent. Sci*. 2020;9(10).
8. Fidel SR, Sassone L, Alvares GR, Guimaraes RP, Fidel RA. Use of glass fiber post and composite resin in vertical fractures tooth. *Dent Traumatol*. 2006;22:337-9
9. American Academy of Pediatric Dentistry, Policy on Baby Bottle Tooth Decay/ECC; 2008
10. Mishra A, Pandey R, Pandey N, Jain E. A pedoprosthetic rehabilitation in patients with severe early childhood caries (S-ECC). *BMJ Case Rep*. 2013;9
11. Doneria D, Thakur S, Singhal P, Chauhan D. Complete mouth rehabilitation of children with early childhood caries: A case report of three cases. *Int J Pedod Rehabil*. 2017;2:37-40
12. Liu J, Wu H, Wang W. Early childhood caries: a review. *Minerva Pediatr*.;2017 .

© 2021 Gahlod et al.; This is an Open Access article distributed under the terms of the Creative Commons Attribution License (<http://creativecommons.org/licenses/by/4.0>), which permits unrestricted use, distribution, and reproduction in any medium, provided the original work is properly cited.

Peer-review history:

The peer review history for this paper can be accessed here:  
<https://www.sdiarticle4.com/review-history/76443>