

Gingival Squamous Cell Carcinoma: A Missed Diagnosis

Shyam Sunder Salavadi^{1*} • Srinu Sabavath² • Ganesh Ganji³ • Samanvitha Sunkari⁴

¹MDS, Associate Professor, Department of Periodontics, Mamata Dental College and Hospital, Khammam-507002, Telangana, India

²MDS, Post graduate student, Department of Periodontics, Meghana Institute of Dental sciences, Nizamabad, Telangana, India

³MDS, Post graduate student, Department of Periodontics, Kamineni Institute of Dental Sciences, Narketpally, Telangana, India

⁴MDS, Post graduate student, Department of Periodontics, MNR Dental College and Hospital, Sangareddy, Telangana, India

*Corresponding Author; E-mail: dr.samsunder@gmail.com

Received: 1 May 2017; Accepted: 11 August 2017

J Periodontal Implant Dent 2017;9(1):26–28 | doi:10.15171/jpid.2017.005

This article is available from: <http://dentistry.tbzmed.ac.ir/jpid>

© 2017 The Authors. This is an Open Access article distributed under the terms of the Creative Commons Attribution License (<http://creativecommons.org/licenses/by/4.0>), which permits unrestricted use, distribution, and reproduction in any medium, provided the original work is properly cited.

Abstract

Squamous cell carcinoma (SCC) is one of the most common epithelial malignancies affecting the oral cavity with different clinical presentations. Carcinomas of the gingiva constitute approximately 10% of OSCCs and can mimic reactive, inflammatory conditions of the gingiva, leading to a diagnostic delay. Therefore it is of great importance to diagnose the lesion early for good prognosis. This article reports a rare case of gingival OSCC in a 39-year-old male patient mimicking an inflammatory gingival mass.

Key words: Gingiva, malignancy, squamous cell carcinoma.

Introduction

Oral cancer is a serious health concern and is one of the frequent malignant neoplasms affecting structures of the oral cavity. Oral squamous cell carcinoma (OSCC) may account for more than 50% of all the cancer cases, with >90% of occurrence in the oral cavity.^{1,2} The most common sites of occurrence are the latero-ventral surface of the tongue, floor of the mouth and buccal mucosa. A less frequent site to be affected is the gingiva, which comprises about 10% of all OSCCs and 91% of patients with gingival carcinoma are >66 years of age. OSCC is more frequent in males whereas gingival squamous cell carcinoma (GSCC) is more frequent in females.^{3,4} Although gingival carcinoma is a subset of OSCC, it is a unique malignancy with variable clinical presentations and can mimic other lesions, especially those of inflammatory origin.⁵ Hence, it is of utmost importance to diagnose the condition early to initiate immediate treatment, prevent metastasis and improve the prognosis. Here we report a case of gingival SCC

mimicking an inflammatory periodontal lesion in a 39-year-old male patient.

Case Report

A 39-year-old male patient presented to our department with a chief complaint of pain and growth in the upper right posterior region since 4 months previously. His medical history was not significant. The patient had a habit of smoking for 10 years, which was discontinued since a year previously. On extraoral examination a solitary right submandibular lymph node was palpable, which was tender, freely moving and soft in consistency. Intraoral examination revealed a solitary erythematous sessile growth in the region of #17 and #18, involving the interdental, marginal and attached gingiva. Superiorly the growth extended into the buccal vestibule of tooth #17 and inferiorly it involved the marginal and attached gingiva of tooth #17 (Figure 1). The surface over the growth was irregular with pseudomembranous slough, giving a granular appearance. On palpa-

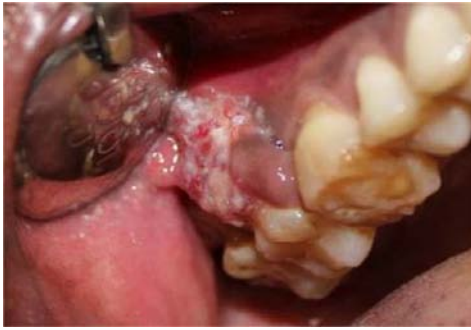

Figure 1. Erythematous, sessile growth in the region of #17 and #18.

tion it was soft in consistency and tender and was bled profusely on probing.

Baseline investigations, such as hemogram, were noncontributory. Orthopantomogram revealed horizontal bone loss in relation to #17, #18 and #35-38 regions and fixed partial denture in relation to #25-27 (Figure 2). Based on the history and clinical and radiographical findings a provisional diagnosis of pyogenic granuloma was considered. Excisional biopsy was carried out and the specimen were sent for histopathological examination which revealed islands and sheets of dysplastic epithelium invading into the underlying connective tissue stroma with keratin pearl formation (Figure 3).

Discussion

Oral squamous cell carcinoma (OSCC) is one of the most aggressive malignancies worldwide and accounts for more than 90% of all oral cancers. It is considered as the sixth leading cause of cancer mortality worldwide and the second leading cause of cancer mortality in India.⁶ OSCC is defined as a malignant epithelial neoplasm exhibiting squamous differentiation characterized by the formation of keratin and the presence of intercellular bridges.^{2,3,7} OSCC

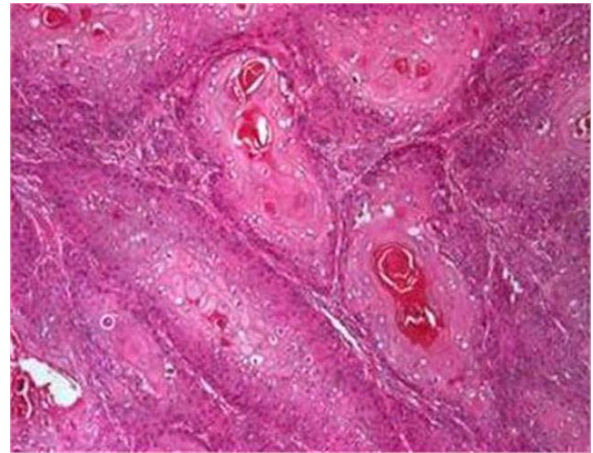


Figure 3. Histopathological picture (40x) showing islands of squamous epithelium in the connective tissue

predominantly affects men (M: F= 1.5:1) over 45 years age of , whereas gingival squamous cell carcinoma is predominantly seen in females over 50 years of age.³

The most common etiologic factors associated with SCC are smoking, smokeless tobacco use, chewing pan (a combination which includes calcium hydroxide, areca nut, and betel leaf). Factors which play a less important role are exposure to ultraviolet radiation, oncogenic viruses, iron deficiency, candidal infections and immunosuppression. Tobacco and alcohol are the two best known collaborative risk factors of OSCC.^{2,8} In the present case, the patient had a history of smoking. The most common sites of OSCC are buccal mucosa, floor of the mouth, tongue, alveolar ridge and the hard and soft palates, whereas gingiva, retromolar area and the buccal and labial mucosa are less frequently involved.^{9,10} In the present case, OSCC was manifested on the gingiva which is a rare site to occur. OSCC of the gingiva more frequently involves the

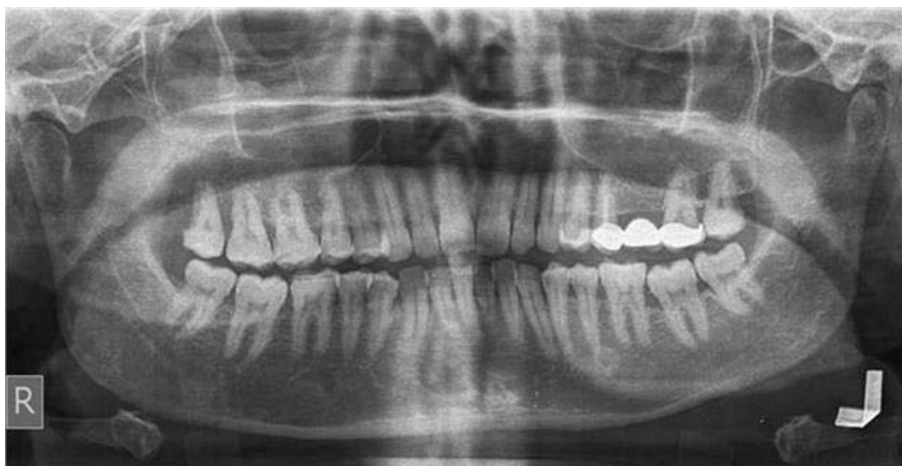

Figure 2. OPG showing horizontal bone loss in relation to 17, 18, 35-38

mandible than the maxilla and is mainly seen in females over 50 years of age.¹ The present case was not consistent with the literature, as it was manifested on maxillary gingiva of a male patient <50 years of age. OSCC of the gingiva is often asymptomatic as it is insidious in onset, and initially it can present as an intraoral mass or swelling and ulceration. In the case reported here the lesion was manifested as a growth on the gingiva. Most often the diagnosis of gingival OSCC is either missed or delayed as in the present case due its similarity to other common inflammatory lesions of the gingiva like periodontitis, pyogenic granuloma, gingivitis and benign hyperplasias of the gingiva. Gingival OSCC is more aggressive and has a higher risk of metastasis due to its proximity to the underlying periosteum and bone.^{2,4} OSCC of gingiva may lead to ill-fitting dentures and mobility of teeth by eroding the underlying bone.¹¹ In the present case there was no erosion of the underlying bone. Radiographically OSCC of the gingiva resembles periodontal disease giving a floating tooth appearance,¹² which was not evident in the present case. Depending on the extent of tumor resemblance to the tissue of origin, OSCC is divided into 3 stages histopathologically. The tumor is well-differentiated, moderately-differentiated or poorly-differentiated. Well-differentiated tumors closely resemble their tissue of origin. They grow and metastasize slowly. Contrarily, poorly differentiated tumors are considered as immature and do not resemble their tissue of origin. The moderately-differentiated tumor lies between these two extremes. In our case it was a well-differentiated type.¹³ The prognosis of OSCC is considered as poor on lymph node metastasis and lesions measuring less than 1 cm have a long-term prognosis as they are easy to cure.³ The prognosis in the present case was expected to be good considering its differentiating type, absence of metastasis and smaller size of the lesion.

Conclusion

OSCC of the gingiva is an aggressive lesion with a

varied clinical presentation, mimicking an inflammatory lesion as in the case reported here. Therefore, oral clinicians should be vigilant and cautious when dealing with such suspicious lesions by regular follow-ups and monitoring. To conclude, the present case alerts all the oral clinicians regarding the importance of submitting the gingival growths for histopathological examination as an aid to prevent delayed diagnosis so as to provide early treatment.

References

1. Rakhewar PS, Kanjalkar V, Syed R. Gingival Squamous Cell Carcinoma: A Case Report. *IOSR Journal of Dental and Medical Sciences (JDMS)* 2012;1(6):21-3.
2. Koduganti RR, Sehwat S, Reddy PV. Gingival squamous cell carcinoma: A diagnostic impediment. *J Indian Society of Periodontol* 2012;16(1):104-7.
3. Sankpal SD, Gangavati R, Thorat S, Kamat W. Gingival Oral Squamous Cell Carcinoma: A Review. *European J Biomed Pharma Sci.* 2016;3(1):397-9.
4. Bharanidharan R, Dineshkumar T, Raghavendhar K, Kumar AR. Squamous cell carcinoma of the gingiva: A diagnostic enigma. *J Oral Maxillofac Pathol* 2015;19:267.
5. O'Sullivan B, Shah J. New TNM staging criteria for head and neck tumors. *Semin Surg Oncol* 2003;21:30-42.
6. Warnakulasuriya S. Global epidemiology of oral and oropharyngeal cancer. *Oral Oncol* 2009;45:309-16.
7. Rajendran R, Sivapathasundaram B. In Shafer's text-book of Oral pathology, 5th ed, India: Reed-Elsevier India Private Limited; 2006.p. 143.
8. Keser G, Pekiner FN, Ozbayrak S, Alatli C. Squamous Cell Carcinoma of the Gingiva: A Case Report and Literature Review. *Journal of Marmara University Institute of Health Sciences* 2015;5(4):290-5.
9. Rikardsen OG, Bjerkli IH, Lars Uhlin-Hansen L, Hadler-Olsen E, Steigen SE. Clinicopathological characteristics of oral squamous cell carcinoma in Northern Norway: a retrospective study. *BMC Oral Health.* 2014;14:103.
10. Bello IO, Soini Y, Salo T. Prognostic evaluation of oral tongue cancer: means, markers and perspectives (I). *Oral Oncol* 2010; 46(9):630-5.
11. Yoon TYH, Bhattacharyya I, Katz J, Towle HJ, Islam MN. Squamous cell carcinoma of the gingival presenting as localized periodontal disease. *Quintessence International* 2007;38(2):97-102.
12. Langlais RP, Langland OE, Nortje CJ. Diagnostic imaging of the jaws. 1st ed. Williams and Wilkins; 1995.p.33.
13. Neville BW, Damm DD, Allen C, Bouquet J. *Oral and Maxillofacial Pathology*, 2nd ed. Elsevier; 2008. p.451-2.