

Research Article

A Combination of Coconut Fiber Suture and Tamarind Seed Gel with Dehydrated Human Amnion Membrane for Wound Surgery in Rats

Raghu Babu Pothireddy¹,¹ Angeline Julius,² Manu Thomas Mathai,¹
Ganesh Lakshmanan,³ and Beimnet Asfaw Hailemariam⁴

¹Department of Zoology, Madras Christian College, Affiliated to University of Madras, Chennai 600059, Tamil Nadu, India

²Centre for Materials Engineering and Regenerative Medicine, Bharath Institute of Higher Education and Research, Chennai 600126, Tamil Nadu, India

³Department of Anatomy, Asan Memorial Dental College and Hospital, Chennai 603105, Tamil Nadu, India

⁴Institute of Biotechnology, Addis Ababa University, Addis Ababa, Ethiopia

Correspondence should be addressed to Raghu Babu Pothireddy; raghubabu_84@yahoo.com and Beimnet Asfaw Hailemariam; beimnet.asfaw@aau.edu.et

Received 8 July 2021; Accepted 10 August 2021; Published 19 August 2021

Academic Editor: Ravichandran M

Copyright © 2021 Raghu Babu Pothireddy et al. This is an open access article distributed under the Creative Commons Attribution License, which permits unrestricted use, distribution, and reproduction in any medium, provided the original work is properly cited.

Today, there are over 2,000 different biomaterials used for various medical applications, but none of these biomaterials are 100% compatible with all human beings. Coconut fiber is widely available but has not been tested as a safe natural alternative for sutures. Immature coconut fiber is nonabsorbable and is effective for cuts and open wounds when used in combination with dehydrated human amnion membrane (dHAM). Immature coconut fiber, tamarind seed polysaccharide (TSP), and dHAM were prepared to test their combinational effect on wound healing in rats. TSP enhanced cell viability, proliferation, and migration in human skin cells and cured wounds both individually and in combination with dHAM. An antibiotic-free combination of the human amniotic membrane with intact epithelium, tamarind seed polysaccharide, and immature coconut fiber provided faster wound healing. Significantly higher wound healing was seen on the 11th day based on an initial 10 mm biopsy punch surgery in Wistar rats compared to control groups. Histological studies revealed thickened dermis edges with more neutrophil infiltration. Collagen deposition in the dermis was homogeneous across the excised skin tissue in the test group, again attesting to the utility of this procedure. This research signifies the use of TSP gel together with the amnion membrane representing a “smart patch” with wound healing potential, which would encourage further research on the smart patch made using a combination of plant and animal biological materials.

1. Introduction

Wound healing is a natural and complex process of tissue recovery of injured tissues involving growth factors and cytokines, released at the injured site. Delayed or impaired wound healing may occur due to several reasons like chronic medical conditions and medications that inhibit the healing process [1]. Medicinal plants with wound healing properties have been used to treat acute and chronic wounds for the past three decades [2, 3]. Among the world population, 70 to 80% depend on medicinal plants for the management of

various ailments since ancient time [3]. Wound dressings made of pectin and collagen enhance wound healing but are highly expensive [4]. Identification of potent and effective natural compounds for wound healing would benefit in the management of wounds in a cost-effective manner.

The present research relates to the use of plant materials and biological membrane together as biocompatible biomaterials for wound healing. Coconut fibers are available plenty in India and are used for different purposes. The scope of this research is to come up with this novel use of immature coconut fiber along with other novel combinations of

biomaterials for cut and open wound healing studies. Coconut fiber of green coconuts is immature and tough because of the presence of lignin [5] and the presence of biodegradable hemicellulose and cellulose that contribute to wound healing [6, 7]. The coconut fiber material has never been thought of as a suture, nor has been used as a cheaper, safer, economically viable, and easily available suture material to date. This green, alternative, nonabsorbable suture (Indian Patent no. 298076) is effective when compared with commercial nonabsorbable sutures such as prolene, silk, and nylon.

Xyloglucans of *Tamarindus indica L.* have been currently explored for its property of wound healing, individually or in combination to heal wounds by enhancing cell viability, proliferation, and migration in human skin keratinocytes [8]. Xyloglucans are polysaccharides, which are the main constituents of the tamarind seed kernel and are rich in xylose and galactoxylose substituents. Due to their mechanical properties, they have a wide application in hydrogel production, films, and as drug delivery agents for slow drug delivery [9]. Xyloglucan is abundantly found in plant cell walls, contains ($\beta 1 \rightarrow 4$)-linked d-glucan substituted with xylose, possesses mucoadhesive properties mainly due to the mucin-like structure, and belongs to the group of polysaccharides, referred to as hemicelluloses [10]. The mucoadhesive property of xyloglucan has permitted its use as an adhesive with antimicrobial property to prevent bacterial adherence and invasion [11]. Xyloglucans when introduced into nanofibrillated cellulose (NFC) through adsorption and presorption to strengthen the NFC revealed highest adsorption, reinforcement, enhancement of cell growth, and proliferation for wound healing [12].

Hemicellulose films have proved to be haemostatic, absorptive, and bactericidal and have shown effective epithelial wound healing in leukaemia patients with herpes zoster infections [13]. A natural hydrogel from honey in combination with polyvinyl pyrrolidone, polyethylene glycol, and agar solution showed a significant wound healing effect compared to the control groups. The hydrogel demonstrated histopathologically confirmed reduction in wound size and has been recommended for burn injuries due to a high fluid absorption rate [14]. Furthermore, a porous hydrogel (size: 32.8–101.6 μm) from a mixture of chitosan and xyloglucan with good mechanical properties has enhanced the properties of chitosan with the addition of xyloglucan, without affecting its antimicrobial activity for wound dressing [15]. Since xyloglucans have shown positive effects on wound healing [16], hydrogels of xyloglucans could exhibit wound healing action and also act as a vector for slow drug delivery to aid healing. This work focuses on extraction, identification of polysaccharide consisting of xyloglucan from the kernel of tamarind, preparation of the wound gel by crosslinking with epichlorohydrin, and providing a platform for the intervention of efficacious and cost-effective wound healing agent.

The human amniotic membrane (HAM) has been proved to be an excellent source of material for wound therapy [17], since it induces reepithelialization meanwhile processing antiangiogenic and antimicrobial properties. The

human amniotic membrane (HAM) lacks immunogenicity and acts as a substrate for growth, adhesion, and migration [18]. The wound healing ability of HAM accounts for the presence of growth factors such as EGF, KGF, and HGF to aid wound healing [19]. The three biomaterials used for the study are biowastes, which were used positively for wound healing, and this research could cause a great impact on the identification of novel biomaterials that could work in combination to provide high healing efficiency.

This study employs plant and animal biomaterials to treat cut and open wounds. Figure 1 illustrates the preparation of immature coconut fiber, tamarind seed polysaccharide, and dehydrated human amnion membrane (dHAM) to test wound healing in rats. The use of plant and human tissue combinations for wound healing and management had made this research novel in its attribute that has not been performed or reported before.

2. Materials and Methods

2.1. Preparation and Evaluation of Physical Parameters of Immature Coconut Fiber

2.1.1. Preparation of Immature Coconut Fiber Suture. The fiber of green coconuts was removed from the shell of the nut and was soaked in water for 24 to 48 hours to allow the fiber to be separated into strands. The fiber strands are then soaked into 70% isopropyl alcohol for decolorization for 5 hours and dried in a hot air oven between 40 and 50°C for 1 hour.

2.1.2. Determination of Tensile Strength of Coconut Fiber Using Universal Testing Machine (UTM). The thickness of each fiber was measured (in diameter) using a dial thickness gauge. The average diameter of the fibers ($n = 3$) was noted to determine the tensile strength. Each fiber was inserted into the universal testing machine and ensured that the ends were gripped symmetrically so that the tension force was distributed uniformly over the cross section. The load cell value was set to zero, and the speed of the moving grip was 10 mm/min. Changes in the test length were noted throughout the test and were continued until the break of the test sample. Three samples of thin and thick immature coconut fibers were taken in comparison with prolene and silk sutures [20].

2.1.3. Skin Holding Effect of Coconut Fiber, Prolene, and Silk Sutures in Rats. Sprague Dawley (SD) rats (14 numbers) were used for the study, and they were anesthetized with ketamine and xylazine and acclimatized for 7 days. Animals were randomly divided into two groups, with 7 animals in each group. Group 1 was tested with thin coconut fiber in comparison with the prolene suture. Group 2 was tested with thick coconut fiber in comparison with silk suture.

Two 3.5 cm long parallel full-thickness skin incisions were made under aseptic conditions on the back of the experimental rat. The incisions were closed immediately by 4 simple sutures (Figure 2). Rats were sacrificed by carbon dioxide inhalation. The skin wounds were removed from the

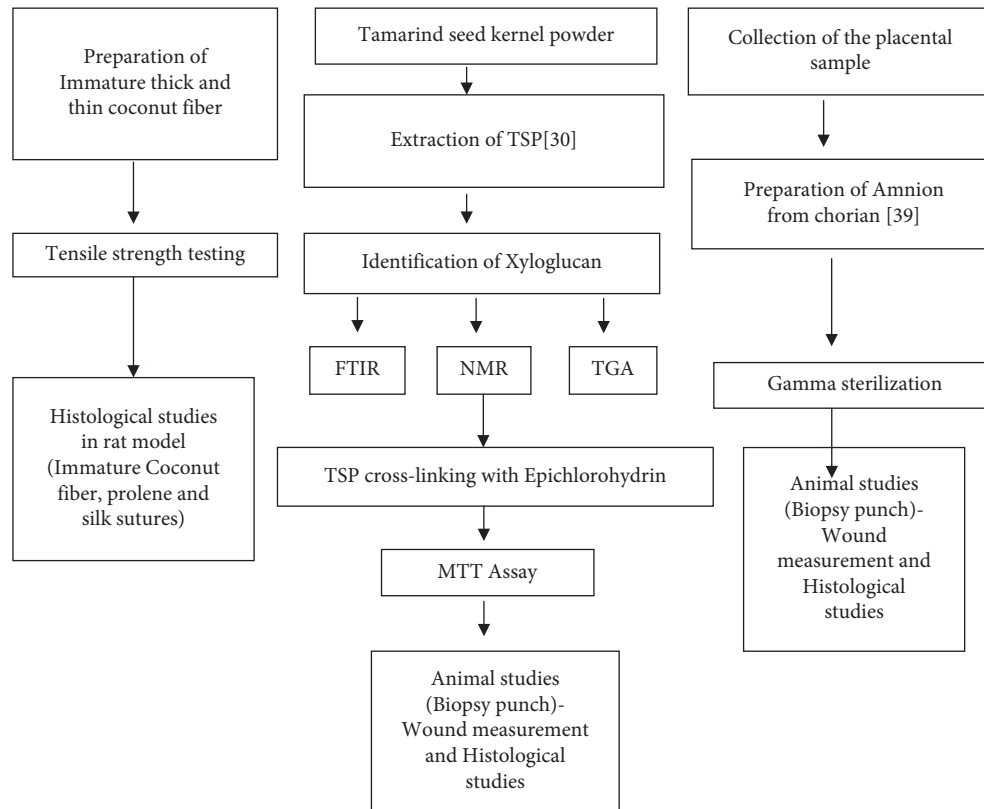


FIGURE 1: Combination therapy for cut and open wounds. TSP: tamarind seed polysaccharide; FTIR: Fourier-transform infrared spectroscopy; NMR: nuclear magnetic resonance; TGA: thermogravimetric analysis; MTT: 3-(4,5-dimethylthiazol-2-yl)-2,5-diphenyltetrazolium bromide.

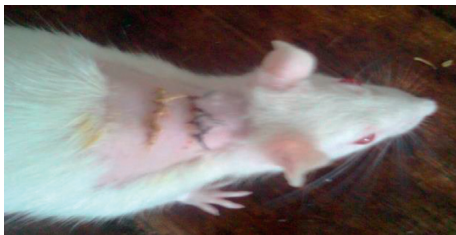


FIGURE 2: SD rat sutured with immature coconut fiber and silk suture.

body after 24, 48, 72, 96, 120, 144, and 168 h ($n = 1/\text{group}/\text{time point}$). Histopathological analyses were performed using hematoxylin-eosin, Azur, PAS, and van Gieson stained slides.

2.2. TSP Gel Wound Healing Ability in Wistar Rats. Male Wistar albino rats (90 days old) weighing around 200 g to 250 g were used for the study. The animals ($n = 3$) were fed with standard laboratory diet in the pellet form, and the rats had access to drinking water and libitum. Under intramuscular injections of a combination of ketamine (40 mg/kg body weight (b.w) and xylazine (15 mg/kg b.w), the dorsal aspect of the rats was shaved. An excision punch biopsy was done passing through both sides of the lifted midline, achieving two 8 mm diameter excision wound side by side to

its spine below the neck region in the dorsal aspect [21, 22]. One side of the excision was treated with the prepared TSP gel (approximately 0.25 ml of thawed gel twice daily for 5 days) and the other side was not treated (control).

Postcreation of the wound, the animals were given a broad-spectrum antibiotic, amoxicillin (0.001 mL/kg b.w, intramuscularly, single dose), and anti-inflammatory/analgesic agent, piroxicam (3 mg/kg b.w, intramuscularly daily for 3 days), and monitored for any signs of active infection for the first two days. At the end of the study period (after 7 days), the animals were euthanized using a gas chamber filled with isoflurane fumes. The wound area with the surrounding tissue was excised to its full depth and fixed in 10% neutral buffered formalin and processed for routine histopathology.

2.3. Combined Wound Surgery with the Prepared Biomaterials in the Rat Model. The wound was created using a 10 mm biopsy punch on animals used for the study. One of the excised wounds was treated with the prepared biomaterials (application of approximately 0.25 ml TSP gel on wound area with dHAM placed on top and sutured with immature coconut fiber). Another excision wound was untreated (control) in Wistar rats of group 1 ($n = 3$). Similarly, one excised wound of group 2 animals ($n = 3$) was treated with TSP gel, applied on the surface of the wound area (approximately 0.25 ml) with dHAM placed on top and sutured

with immature coconut fiber. The other wound incision was treated with the commercial silicone gel membrane and sutured with the commercial silk suture.

Postcreation of the wound, the animals were given a broad-spectrum antibiotic, amoxicillin (0.001 mL/kg b.w, intramuscularly, single dose), and anti-inflammatory/analgesic agent, piroxicam (3 mg/kg b.w, intramuscularly daily for 3 days), and monitored for any signs of active infection for the first two days. At the end of the study period (after 11 days), the animals were euthanized using a gas chamber filled with isoflurane fumes. The wound area with the surrounding tissue was excised to its full depth and fixed in 10% neutral buffered formalin and processed for routine histopathological examinations.

3. Results and Discussion

3.1. Analysis of Immature Coconut Fiber

3.1.1. Mechanical Testing of Immature Coconut Fiber. The tensile strength of the immature coconut fiber was tested using the universal testing machine (UTM). Table 1 lists the parameters for tensile strength estimation.

3.1.2. Histopathological Examination of Sutures in Wistar Rats. The skin sections from all the groups revealed spurs of epithelial cell migration towards the wound edges in the epidermal layer and acute neutrophilic infiltration in the dermis and presence of necrotic myofibers of the injured skeletal muscles in the deepest part of the wounds from day 1 to day 3 with similar severity grades.

On days 4 to 6, the epithelial cell proliferation resulted in a thickened epidermal layer. While in the dermis, neutrophilic infiltrations were largely replaced by macrophages along with the formation and invasion of granulation tissue. Maximal neovascularization and collagen production were observed in all three sutured skin samples.

On day 7, the epidermal layer recovered its normal thickness (re-epithelialization) and differentiation with self-keratinisation for the immature coconut fiber treated groups equal to the silk and prolene treated groups. The dermal layer revealed the remodelling phase with the presence of diffused and organized collagen fibers with granulation tissue formation (Figures 3–6).

3.2. TSP Gel Wound Healing Ability in Wistar Rats. TSP gel application on an 8 mm wound on the right side of the animals ($n=3$) resulted in gradual wound reduction compared to the nontreated control. The wound site measurement of the control and the treated on the 7th day reveal exceptional wound healing property of TSP. The treated site had its size reduced to 3.5 mm (± 0.13) on an average, while the nontreated control had a wound size of 6.5 mm (± 0.22), which is almost double the size of the TSP treated site, revealing the wound healing ability of TSP. Difference between the two groups was tested using the students t -test and was found to be statistically significant ($p < 0.001$), revealing the wound healing ability of TSP (Figure 7).

3.3. Histological Investigation. The epidermis of the control animals was thickened at its cut edges. The dermis close to the excision area showed rich polymorph nuclear infiltration. A demarcation line was formed, which separated the necrotic slough tissue from viable tissue. Mild fibroblast proliferation was noted in the dermis region beneath the wound. Neovascularisation in the form of capillary blood vessel formation was noted. However, new collagen formation was minimally seen (Figure 8(a)).

In TSP gel treated animals, the wound edges are approximated and the dermis edges are thickened with more polymorph nuclear infiltration. Fibroblast proliferation is well noted with collagen deposition noted along the wound area. New blood vessel formation was well marked (Figure 8(b)).

3.4. Combination Therapy Involving Natural Biomaterials for Wound Management. Group I animals ($n=3$), 10 mm wounds, sutured with immature coconut fiber with prepared dHAM and TSP gel in combination, had better healing after 11 days. Profound wound reduction was observed in the treated wound area with a measurement of 2 mm (± 0.10), differing much with the nontreated control measuring 6 mm (± 0.10) (Figure 9(c)). Difference between the two groups was tested using the Student t -test and was found to be statistically significant ($p < 0.001$). Following the study, the animals were euthanized, and the wound area was processed for histopathological examinations.

Group II animals ($n=3$) with 10 mm wound excisions treated with dHAM, TSP gel, and immature coconut fiber (Figure 10(a)) were compared with 10 mm wound excisions, treated with silicone gel membrane and silk suture as the positive control. Wound measuring 1.5 mm (± 0.17) at the test site (dHAM + TSP gel + coconut fiber) in comparison with the positive control (silicone gel membrane + Silk suture) after 11 days of treatment reveal the wound healing potency of the biomaterials tested (Figure 10(c)). There is no statistical difference between the groups ($p > 0.05$).

3.5. Histopathology Investigation of Group I Samples. Control animals exhibited thickened epidermis at its cut edges (Figure 11(a)). The dermis close to the excision area showed rich polymorph nuclear infiltration. A demarcation line was formed, which separated the necrotic slough tissue from the viable tissue. Mild fibroblast proliferation was noted in the dermis region beneath the wound. Neovascularisation in the form of capillary blood vessel formation was noted. However, new collagen formation was minimally seen.

In test (dHAM + TSP + coconut fiber treated) animals, the wound edges were thickened with high epithelialization features (Figure 11(b)). The PMNL infiltration was seen in clusters and evenly dispersed across the wound area. Fibroblast proliferation was high in the dermis region with added neovascularisation across the dermis and also in the underlying subcutaneous matrix. The dermis edges are thickened with more polymorph nuclear infiltration. Circular clusters of collagen deposition in the dermis are noted all over the excised skin tissue.

TABLE 1: Parameters for tensile strength estimation.

Material	Average diameter (mm)	Average length	Rate (Speed) (mm/min)	Tensile strength (N)
Coconut thin fiber (Non absorbable)	0.126	18 cm to 25 cm	10	1.63
Prolene (Non absorbable) monofilament	0.099	45cm	10	1.96
Coconut thick fiber (Non absorbable)	0.248	18 cm to 25 cm	10	7.40
Silk braided (Non absorbable)	0.225	45 cm	10	20.12

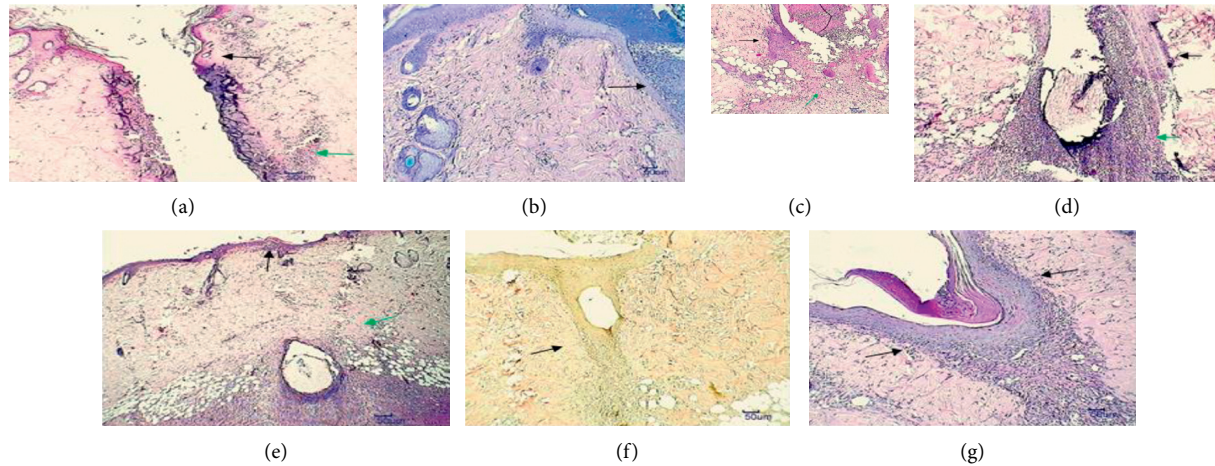


FIGURE 3: Histopathological indications of immature coconut fiber (multifilament) sutured skin area sections. (a) 24 hrs—hematoxylin and eosin (H and E) 10x, necrosis of epidermal and dermal cells, mild neutrophilic infiltration. (b) 48 hrs—Giemsa 10x, epithelial cell migration and moderate neutrophilic infiltration. (c) 72 hrs—H and E 10x, moderate epidermal proliferation, mild granulation tissue invasion. (d) 96 hrs—H and E 10x, epidermal layer thickening, moderate granulation tissue formation. (e) 120 hrs—H and E 10x, moderate epidermal keratinization, mild collagen proliferation and granulation tissue. (f) 144 hrs—van Gieson 10x, moderate amount of diffuse collagen deposition with granulation tissue formation. (g) 168 hrs—PAS 10x, moderate amount of new blood vessels with granulation tissue.

3.6. Histopathology Investigation of Group II Samples. In the test (dHAM + TSP gel + coconut fiber) treated animals, the wound edges are thickened with high epithelialization features. The PMNL infiltration was seen in clusters and evenly dispersed across the wound area. Fibroblast proliferation was high in the dermis region with added neovascularisation across the dermis and also in the underlying subcutaneous matrix. The dermis edges are thickened with more polymorph nuclear infiltration. Collagen deposition in the dermis is homogeneous and was noted all over the excised skin tissue (Figure 12(a)).

In the positive control (silicone gel membrane + silk suture) treated animals, the edges were in close approximation with a great reduction in wound space. Healing is hastened with a good amount of collagen deposition all over the excision space. PMNL infiltration has started to clear off with signs of thickened epithelium development (Figure 12(b)).

The complex and coordinated process of wound healing involves different factors and steps and requires additional care to prevent the worsening of the wound and abnormal scar development. Though traditional therapies for wound care have shown beneficial effects, there remain certain challenges that require novel therapeutic approaches. Wound closure techniques have evolved initially from suture materials comprising of absorbable and nonabsorbable properties [23].

Noncontaminated and small skin wounds are ideally sealed by topical skin adhesives or glues that are cost-effective to prevent further infection. Topical skin adhesives are also proved to be effectively used along with sutures. Since the degree of healing depends on the affected area, therapeutic process, and compatible material used for treatment, interventions on combination therapy for wound management would be a better option to contain and treat wounds in a multidirectional perspective [24].

Large size wounds pose a serious problem and, preferably, an autograft is installed at the wound site. Minimal or lack of graft tissue for treatment had resulted in the use of allograft human amnion/chorion tissue as an alternative to autografts, which could modulate inflammation and enhance healing of tissues, thus promoting wound healing. Bioavailability of factors of wound healing and the increased shelf life of the naive and immunomodulatory human amnion membrane have been major reasons for its clinical use [25].

Our multidirectional research has employed a combinational treatment approach for cut and open wound management, combining the use of TSP gel, the human amnion membrane, and the novel immature coconut fiber suture.

Though topical therapy is common in wound management, our objective was to provide the best natural

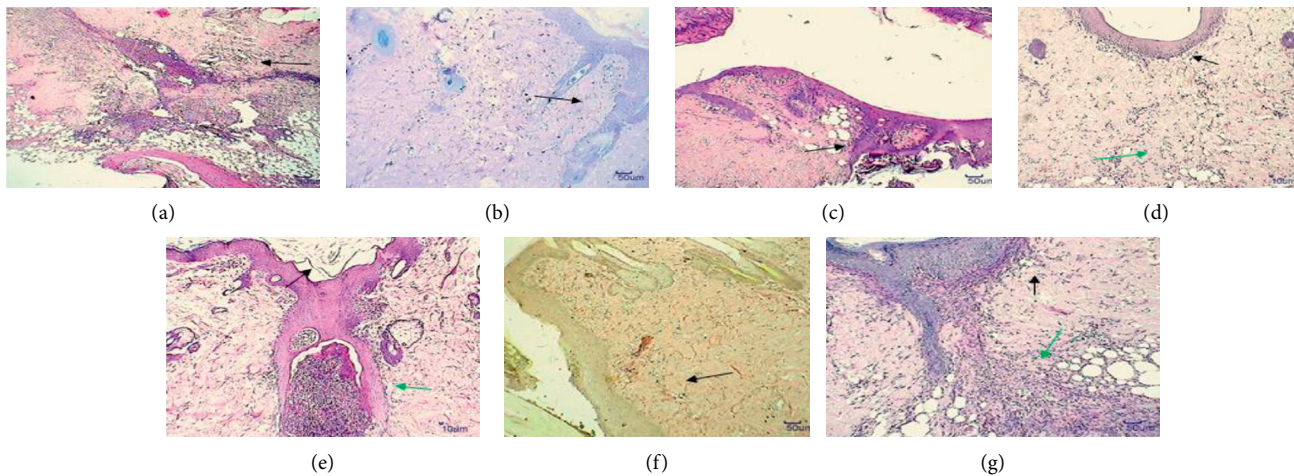


FIGURE 4: Histopathological indications on immature coconut fiber (monofilament) sutured skin area sections. (a) 24 hrs—H and E 10x, necrosis of epidermal and dermal cells with scab formation and severe neutrophilic infiltration. (b) Epithelial cell migration and proliferation with severe neutrophilic infiltration. (c) 72 hrs—H and E 10x, mild epidermal proliferation with granulation tissue invasion. (d) 96 hrs—H and E 10x, epidermal layer thickening, mild granulation tissue formation. (e) 120 hrs—H and E 10x, severe epidermal keratinization, moderate invasion of granulation tissue. (f) 144 hrs—van Gieson 10x, organized collagen proliferation. (g) 168 hrs—PAS 10x, moderate amount of neovascularization, granulation tissue formation.

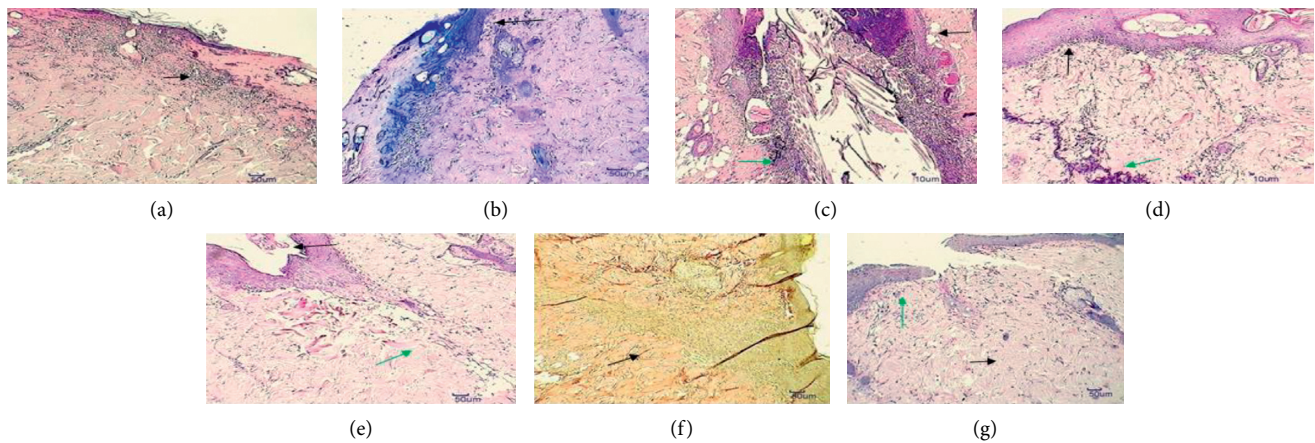


FIGURE 5: Histopathological indications on braided silk sutured skin area sections. (a) 24 hrs—H and E 10x, necrosis of epidermal and dermal cells with scab formation and mild neutrophilic infiltration. (b) 48 hrs—Giemsa 10x, epithelial cell migration with moderate neutrophilic infiltration. (c) 72 hrs—H and E 10x, epidermal proliferation, mild granulation tissue invasion. (d) 96 hrs—H and E 10x, epidermal layer thickening, mild granulation tissue formation. (e) 120 hrs—H and E 10x, severe epidermal keratinization, moderate collagen production. (f) 144 hrs—van Gieson 10x, diffuse moderate collagen production. (g) 168 hrs—PAS 10x, severe collagen production, moderate neovascularization in the dermis.

alternative to the available treatment options involving synthetic materials in wound treatment. Porous silicone membranes play a dual role, serving as epidermal barriers and as a scaffold for delivering therapy to the affected area. Collagen-based silicone gel sheet, comprising of a porous silicone sheet coated with collagen, had been proved to heal different grades of the wound in several studies and decreased hypertrophic scarring when applied to surgical wounds [26]. Treatment using topical silicon sheets date back to the early 1980s, where silicone sheets were used to treat hypertrophic and keloids scars [27]. Studies indicate the improvement of hypertonic and

keloid scars in 85% of the cases treated with silicone gel sheet [28] though reported with skin irritation, a well-known side effect. dHAM allografts have been employed to heal wounds without any complications or rejection even in elderly individuals. The usage of dHAM further can rule out inconveniences and pain, mainly due to the anti-inflammatory properties of the membrane and its action as a barrier covering the nociceptors [17].

Our research uses three different biomaterials for wound therapy, each having its own medicinal value contributing to the wound healing effect. Our novel study investigates and evaluates the use of combination therapy

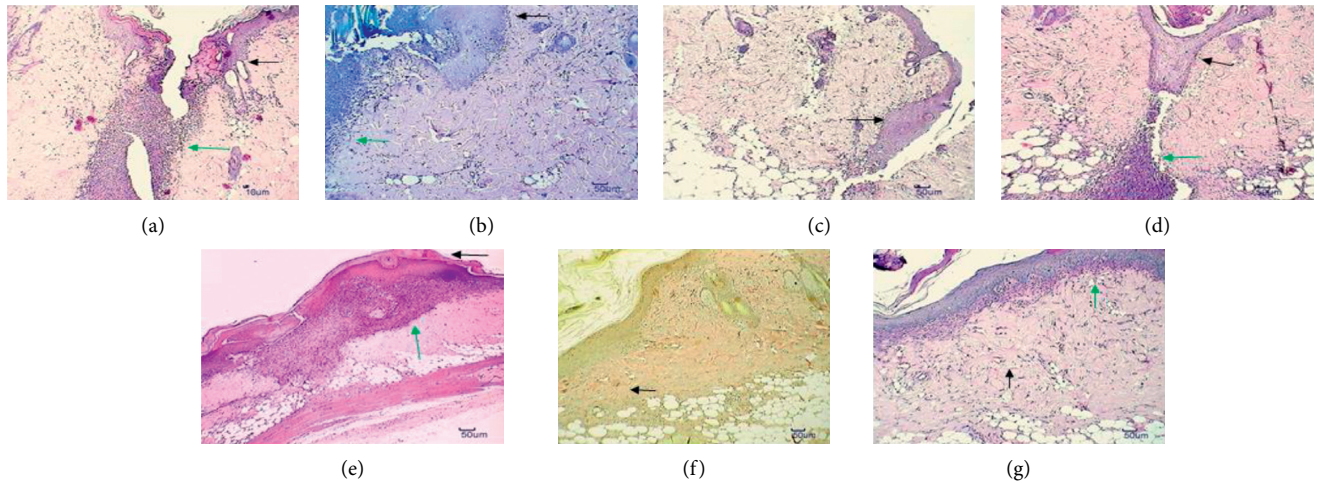


FIGURE 6: Histopathological indications on Prolene suture skin area sections. (a) 24 Hrs—H and E 10x, necrosis of epidermal and dermal cells, severe neutrophilic infiltration. (b) 48 hrs—Giemsa 10x, epithelial cell migration, severe neutrophilic infiltration. (c) 72 hrs—H and E 10x, moderate amount of epidermal proliferation and thickening. (d) 96 hrs—H and E 10x, epidermal layer thickening, mild granulation tissue formation. (e) 120 hrs—H and E 10x, severe epidermal keratinization, moderate granulation tissue formation. (f) 144 hrs—van Gieson 10x, diffuse fibroblast proliferation in the dermis. (g) 160 hrs—PAS 10x, severe collagen production, maximal neovascularization in the dermis.

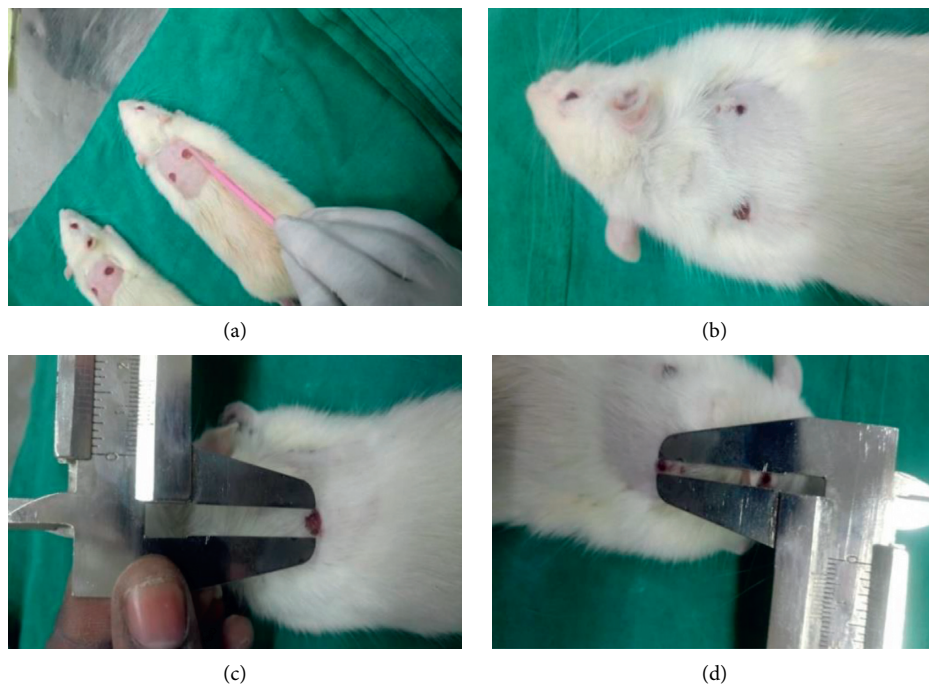


FIGURE 7: TSP gel wound healing ability in Wistar rats. (a) TSP gel application site (right side), (b) wound site reduction at TSP gel applied site (after 7 days), (c) wound site measurement of control (6.5 mm) at 7th day, and (d) wound site measurement of TSP gel applied site (3.5 mm) at 7th day. Values are expressed as mean \pm SE ($n = 3$), where $p \leq 0.001$.

in wound healing and management of cut and open wounds.

Immature coconut fiber, both thin and thick, had satisfying skin holding capacity equal to prolene, a monofilament suture, and silk, a multifilament suture. Neovascularisation, collagen production, and re-epithelialization were observed with the

recovery of the epidermal layer to its normal thickness on the 7th day of the study in all three suture treated groups.

Tamarind seed xyloglucan of tamarind seed kernel powder act as a drug vehicle and influence cell viability, cell migration, and gene expression of human skin keratinocytes and fibroblasts [8]. The use of noncarcinogenic TSP in the

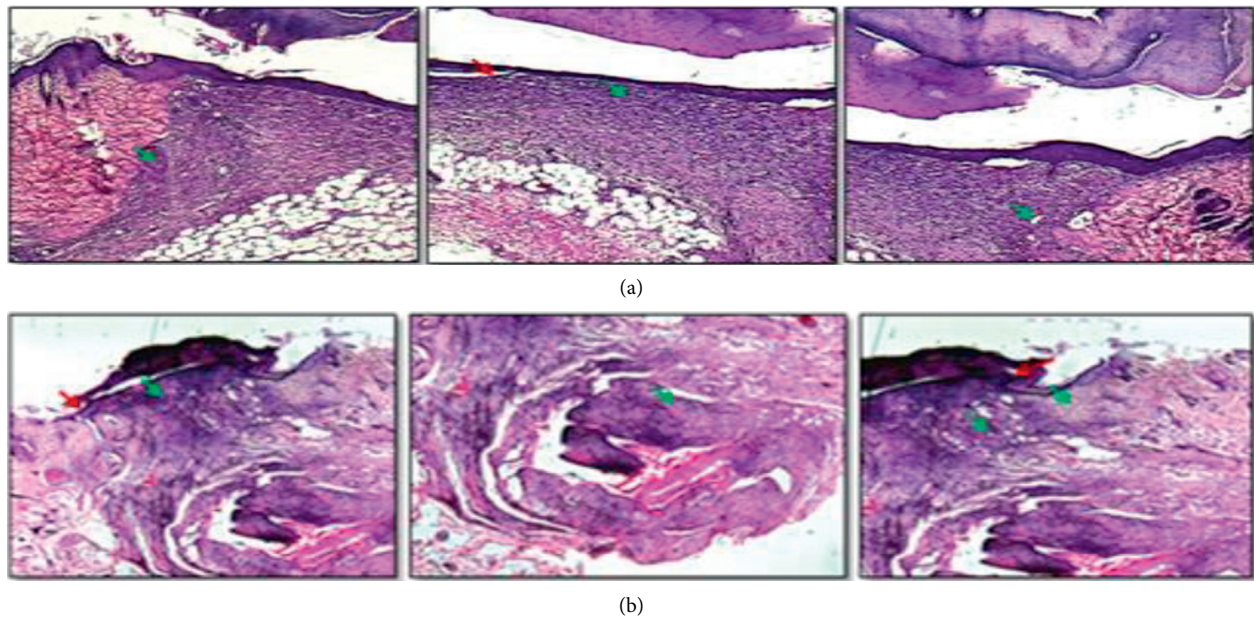


FIGURE 8: (a) Control (untreated) and (b) TSP gel treated: photomicrographs of H &E-stained images showing the wound edges and wound crater. Epithelialization is marked by a red arrow and collagen formation by green arrows.

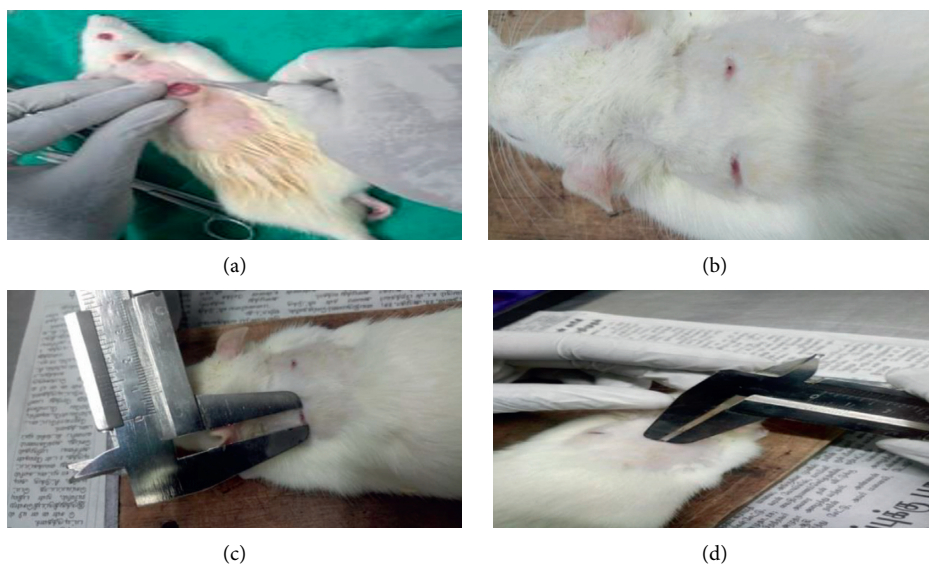


FIGURE 9: Group I animals tested with a combination of dHAM, TSP gel, and immature coconut fiber compared with untreated (control). (a) dHAM surgery on the right side with TSP gel and coconut fiber suture for 10 mm biopsy punch diameter wound. (b) After 11 days, wound reduction site on the right side is better than the nontreated control. (c) Wound site measurement (6 mm) at the nontreated control site after 11 days. (d) Wound site measurement (2 mm) at the test site (dHAM + TSP gel + coconut Fiber) after 11 days. Values are expressed as mean \pm SE ($n = 3$), where $p < 0.001$.

drug delivery system accounts for its mucoadhesive property and drug holding ability [29].

The gel-like consistency of TSP, when mixed with water, add additional advantage to its wound healing property in retaining its characteristics during treatment [30]. It also acts as a carrier in drug delivery as reported by several studies [31, 32]. Its slow drug-delivering action ensures proper and timely delivery with its elasticity, mimicking a scaffold that would benefit in gripping of the treatment site. Additionally,

its bioadhesive nature has been exploited in the development of polymeric films in the treatment of candida vaginitis using nystatin as the drug [31]. Its high drug holding nature has facilitated its use as carriers to substantiate the sustained release of drugs.

A combination of immature coconut fiber, dHAM, and TSP gel healed wounds much faster than the nontreated control, with wound measurements 2 mm (± 0.10) and 6 mm (± 0.10), respectively. Similarly, a 10 mm wound treated with

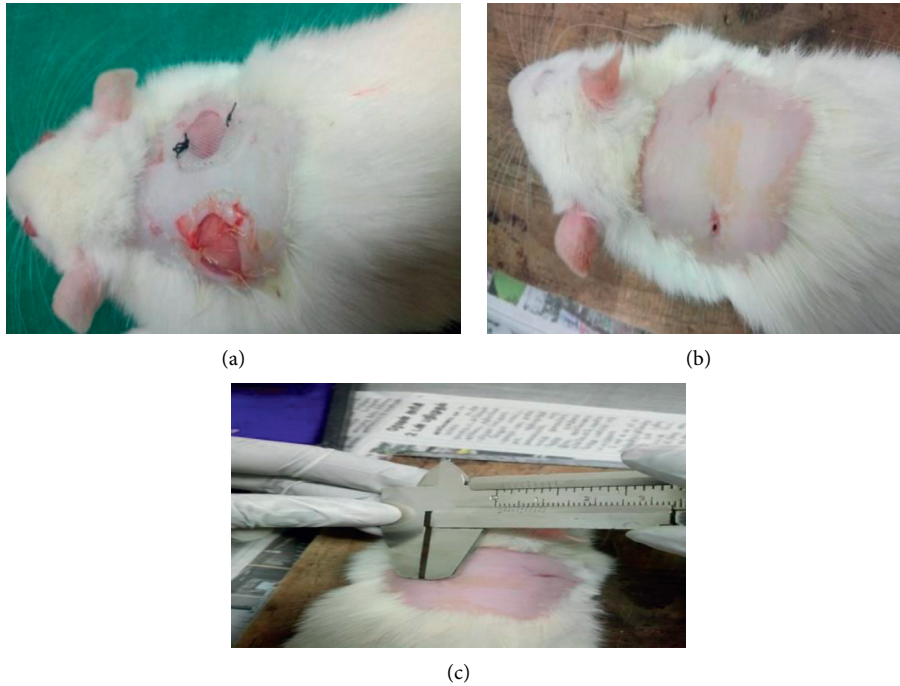


FIGURE 10: Group II animals tested with a combination of dHAM, TSP gel, and immature coconut fiber compared with silk suture and silicone gel membrane (positive control). (a) dHAM + TSP gel + coconut fiber (Left side) and silicone gel membrane + silk suture (right side). (b) After 11 days, the test sample on the left side showed healing in comparison with completely healed positive control on the right side. (c) Wound site measurement (1.5 mm) at the test site (dHAM + TSP gel + coconut fiber) after 11 days. The silicone gel membrane + silk suture site (positive control) was completely healed after 11 days, and hence no measurement was taken. Values are expressed as mean \pm SE ($n = 3$), where $p \leq 0.05$.

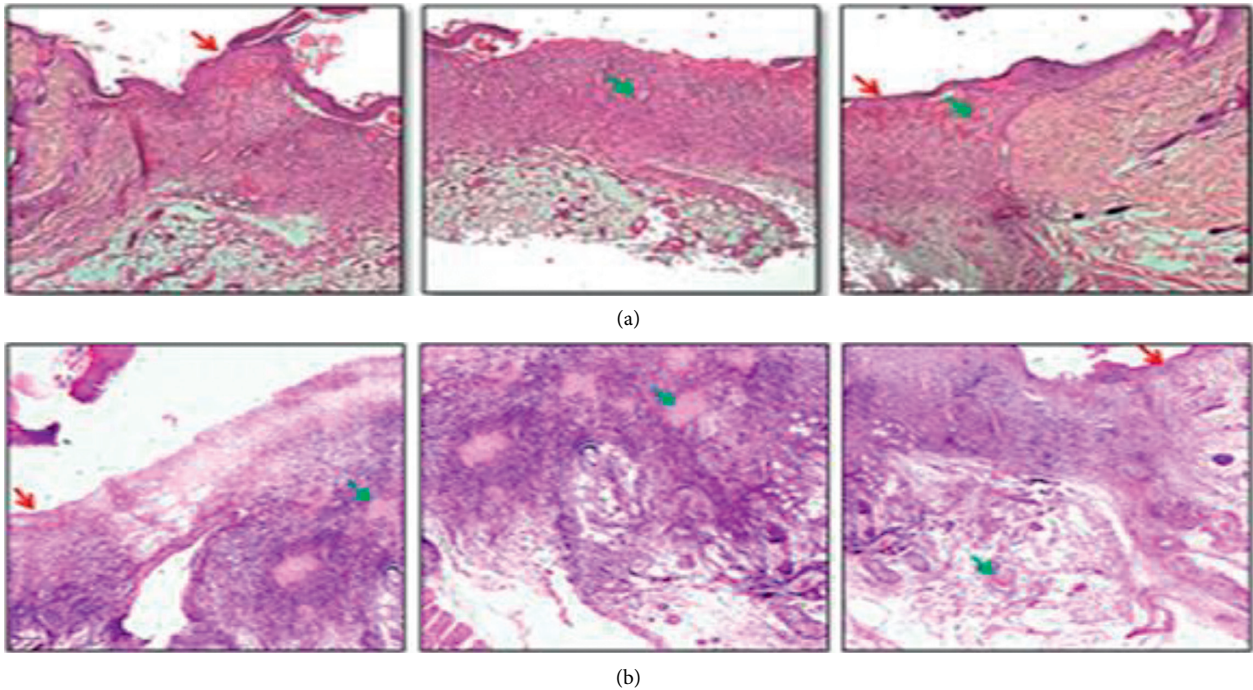


FIGURE 11: (a). Control (untreated) and (b) test (dHAM + TSP gel + coconut fiber): photomicrographs of H and E-stained images showing the wound edges and wound crater. Epithelialization is marked by a red arrow and collagen formation by green arrows.

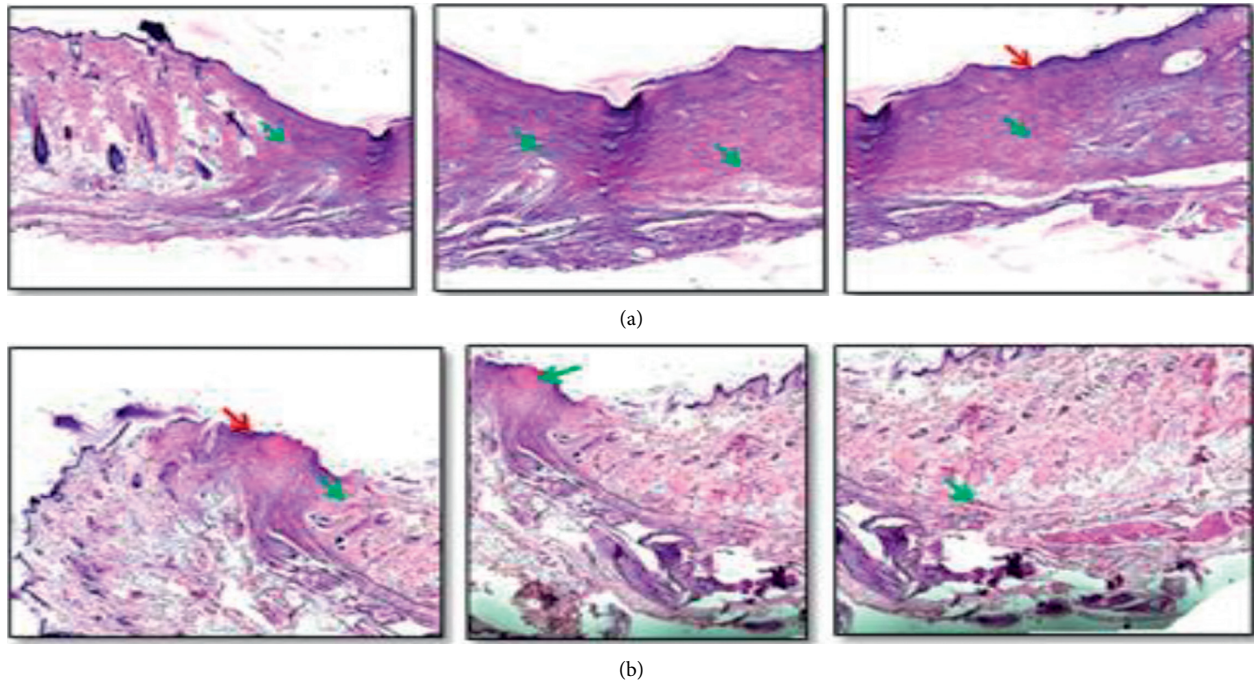


FIGURE 12: (a) Test (dHAM + TSP gel + coconut fiber) and (b) positive control (silicone gel membrane with silk suture): photomicrographs of H and E-stained images showing the wound edges and wound crater. Epithelialization is marked by a red arrow and collagen formation by green arrows.

the biological preparation had rapid healing, having a wound measurement of 1.5 mm (± 0.17), compared to the completely healed wound treated with the positive control, i.e., silk suture with silicone gel membrane. The rigidity, thickness, and the direct pasting of the silicone gel sheet (positive control) during surgery might account for better healing compared to the individual application of test materials (TSP gel and thin dHAM). TSP acts as a carrier for the transport of growth factors and cytokines from the dHAM, and the hydrating potential acts as a shield for preventing skin irritation. Histopathological examinations revealed high epithelialization and thickened wound edges and were similar to the positive control with collagen deposition all over the excised skin tissue. Our study proves the treatment efficiency of the biological preparation comprising of dehydrated human amnion membrane, TSP gel, and fiber suture in wound healing. Animal study results clearly indicate the potency of natural biomaterials in wound healing, resembling treatment with commercial and synthetic biomaterials.

Conventional tissue adhesive patches serve wound management and fixation of medical devices. Tissue adhesives, butylcyanoacrylate and octylcyanoacrylate, were not efficient in decreasing the wound closure time when compared with the tissue bandages [33]. In contrast to the conventional patches, multifunctional smart skin adhesive patches serve multiple functions of being thin, flexible, and incorporate monitoring technology [34]. Smart patches with capabilities of preventing wound infections and the promotion of tissue remodelling are of high value. Recently, smart patches consisting of biomass chitosan microneedle

array with responsive drug delivery with the application of hydrogel has been proved beneficial in wound healing [35]. Wound patches with artificial intelligence have wide application in various disciplines, especially it can be used to monitor and promote wound healing [36]. On the other hand, advanced, multifunctional, next generation smart bandages that could deliver and monitor oxygen in the wound site are under research to be made available as a low-cost alternative for quick healing [37].

Smart hydrogel wound patches can act as a carrier for drug delivery with a combination of drugs and also as a wound healing indicator when incorporated with modified pH indicator dyes to monitor the tissue healing process by the colour transition of the hydrogel patch [38]. This research signifies the use of TSP gel together with the amnion membrane representing a “smart patch” with wound healing potential, which would encourage further research on the smart patch made using a combination of plant and animal biological materials.

4. Conclusion

The natural novel combination of biomaterials (dHAM, TSP gel, and immature coconut fiber suture) showed better wound healing ability than nontreated controls and closely similar wound healing activity to commercial biomaterials in animal studies. Natural biomaterials were tested individually and also in combination and compared with commercial biomaterials used in wound management. The materials are safer and are easily available and can be greatly used by the medical/veterinary community in the near future.

The unresolved wound treatment challenges can be solved by using different treatment approaches involving natural substances as substitutes or adjuvant therapy in current wound care procedures. A “smart patch” consisting of natural wound healers is the need of the hour, and the combination of plant and animal biological materials would improve the search for novel natural materials for wound healing.

5. Limitations

The length of the immature coconut fiber suture could not be more than 25 cm, while commercial sutures are available in different lengths. Treatment procedures involved the application of 0.25 ml TSP gel to the wound and can be tried with different volumes for its best use and effectiveness.

Data Availability

Data used to support the findings of this study are available from the corresponding author upon request.

Conflicts of Interest

The authors declare that they have no conflicts of interest.

Acknowledgments

The authors thank Madras Christian College, affiliated to University of Madras for providing research facilities. Department of Scientific and Industrial Research (DSIR), Government of India, provided funds for coconut fiber research: DSIR/tepp/861/2010, Government of India.

References

- [1] N. Izzah Ibrahim, S. Wong, I. N. Mohamed et al., “Wound healing properties of selected natural products,” *International Journal of Environmental Research and Public Health*, vol. 15, no. 11, p. 2360, 2018.
- [2] T. V. A. Lordani, C. E. De Lara, F. B. P. Ferreira et al., “Therapeutic effects of medicinal plants on cutaneous wound healing in humans: a systematic review,” *Mediators of Inflammation*, vol. 2018, Article ID 7354250, 12 pages, 2018.
- [3] C. Agyare, A. J. Akindele, and V. Steenkamp, “Natural products and/or isolated compounds on wound healing,” *Evidence-Based Complementary and Alternative Medicine*, vol. 2019, Article ID 4594965, 3 pages, 2019.
- [4] J. S. Boateng, K. H. Matthews, H. N. E. Stevens, and G. M. Eccleston, “Wound healing dressings and drug delivery systems: a review,” *Journal of Pharmaceutical Sciences*, vol. 97, no. 8, pp. 2892–2923, 2008.
- [5] Y. Yan, “Developments in fibers for technical nonwovens,” *Advances in Technical Nonwovens*, Elsevier, Amsterdam, Netherlands, pp. 19–96, 2016.
- [6] L. Del Valle, A. Díaz, and J. Puiggalí, “Hydrogels for biomedical applications: cellulose, chitosan, and protein/peptide derivatives,” *Gels*, vol. 3, no. 3, p. 27, 2017.
- [7] D. Melandri, A. De Angelis, R. Orioli et al., “Use of a new hemicellulose dressing (Veloderm) for the treatment of split-thickness skin graft donor sites,” *Burns*, vol. 32, no. 8, pp. 964–972, 2006.
- [8] W. Nie and A. M. Deters, “Tamarind seed xyloglucans promote proliferation and migration of human skin cells through internalization via stimulation of proproliferative signal transduction pathways,” *Dermatology Research and Practice*, vol. 2013, Article ID 359756, 14 pages, 2013.
- [9] V. Gupta, R. Puri, S. Gupta, S. Jain, and G. K. Rao, “Tamarind kernel gum: an upcoming natural polysaccharide,” *Systematic Reviews in Pharmacy*, vol. 1, no. 1, 2010.
- [10] N. Piqué, M. D. C. Gómez-Guillén, and M. P. Montero, “Xyloglucan, a plant polymer with barrier protective properties over the Mucous Membranes: an overview,” *International Journal of Molecular Sciences*, vol. 19, 2018.
- [11] K. P. R. Chowdary and Y. Srinivasa Rao, “Mucoadhesive microspheres for controlled drug delivery,” *Biological and Pharmaceutical Bulletin*, vol. 27, no. 11, pp. 1717–1724, 2004.
- [12] J. Liu, G. Chinga-Carrasco, F. Cheng et al., “Hemicellulose-reinforced nanocellulose hydrogels for wound healing application,” *Cellulose*, vol. 23, no. 5, pp. 3129–3143, 2016.
- [13] J. Chacon and L. Ferreira, “Hemicellulose dressing for skin lesions caused by herpes zoster in a patient with leukemia—an alternative dressing,” *Wounds: A Compendium of Clinical Research and Practice*, vol. 21, no. 1, pp. 10–14, 2009.
- [14] R. Mohd Zohdi, Z. Abu Bakar Zakaria, N. Yusof, N. Mohamed Mustapha, and M. N. H. Abdullah, “Gelam (*Melaleuca spp.*) honey-based hydrogel as burn wound dressing,” *Evidence-Based Complementary and Alternative Medicine*, vol. 2012, Article ID 843025, 7 pages, 2012.
- [15] D. M. Martínez-Ibarra, D. I. Sánchez-Machado, J. López-Cervantes, O. N. Campas-Baypoli, A. Sanches-Silva, and T. J. Madera-Santana, “Hydrogel wound dressings based on chitosan and xyloglucan: development and characterization,” *Journal of Applied Polymer Science*, vol. 136, no. 12, Article ID 47342, 2019.
- [16] S. Burgalassi, L. Raimondi, R. Pirisino, G. Banchelli, E. Boldrini, and M. F. Saettone, “Effect of xyloglucan (tamarind seed polysaccharide) on conjunctival cell adhesion to laminin and on corneal epithelium wound healing,” *European Journal of Ophthalmology*, vol. 10, no. 1, pp. 71–76, 2000.
- [17] A. B. Lyons, L. K. Chipps, R. L. Moy, and J. L. Herrmann, “Dehydrated human amnion/chorion membrane allograft as an aid for wound healing in patients with full-thickness scalp defects after Mohs micrographic surgery,” *JAAD Case Reports*, vol. 4, no. 7, pp. 688–691, 2018.
- [18] C. Malhotra and A. K. Jain, “Human amniotic membrane transplantation: different modalities of its use in ophthalmology,” *World Journal of Transplantation*, vol. 4, no. 2, p. 111, 2014.
- [19] N. Koizumi, T. Inatomi, C. Sotozono, N. J. Fullwood, A. J. Quantock, and S. Kinoshita, “Growth factor mRNA and protein in preserved human amniotic membrane,” *Current Eye Research*, vol. 20, no. 3, pp. 173–177, 2000.
- [20] T. Rihayat, S. Suryani, T. Fauzi et al., “Mechanical properties evaluation of single and hybrid composites polyester reinforced bamboo, PALF and coir fiber,” *IOP Conference Series: Materials Science and Engineering*, IOP Publishing, vol. 334, , Article ID 12081, 2018.
- [21] S. Lodhi, R. S. Pawar, A. P. Jain, and A. K. Singhai, “Wound healing potential of Tephrosia purpurea (Linn.) Pers. in rats,” *Journal of Ethnopharmacology*, vol. 108, no. 2, pp. 204–210, 2006.
- [22] S. Murthy, M. K. Gautam, S. Goel, V. Purohit, H. Sharma, and R. K. Goel, “Evaluation of in vivo wound healing activity of *Bacopa monniera* on different wound model in rats,” *BioMed*

- Research International*, vol. 2013, Article ID 972028, 9 pages, 2013.
- [23] L. Al-Mubarak and M. Al-Haddab, "Cutaneous wound closure materials: an overview and update," *Journal of Cutaneous and Aesthetic Surgery*, vol. 6, no. 4, p. 178, 2013.
- [24] G. Han and R. Ceilley, "Chronic wound healing: a review of current management and treatments," *Advances in Therapy*, vol. 34, no. 3, pp. 599–610, 2017.
- [25] S. Kogan, A. Sood, and M. S. Granick, "Amniotic membrane adjuncts and clinical applications in wound healing: a review of the literature," *Wounds: A Compendium of Clinical Research and Practice*, vol. 30, no. 6, pp. 168–173, 2018.
- [26] J. M. Zurada, D. Kriegel, and I. C. Davis, "Topical treatments for hypertrophic scars," *Journal of the American Academy of Dermatology*, vol. 55, no. 6, pp. 1024–1031, 2006.
- [27] I. Westra, H. Pham, and F. B. Niessen, "Topical silicone sheet application in the treatment of hypertrophic scars and keloids," *Journal of Clinical and Aesthetic Dermatology*, vol. 9, no. 10, p. 28, 2016.
- [28] J. E. Fulton, "Silicone gel sheeting for the prevention and management of evolving hypertrophic and keloid scars," *Dermatologic Surgery*, vol. 21, no. 11, pp. 947–951, 1995.
- [29] M. Sano, E. Miyata, S. Tamano, A. Hagiwara, N. Ito, and T. Shirai, "Lack of carcinogenicity of tamarind seed polysaccharide in B6C3F1 mice," *Food and Chemical Toxicology*, vol. 34, no. 5, pp. 463–467, 1996.
- [30] R. B. Pothireddy, M. T. Mathai, and A. Julius, "Dual property of tamarind seed polysaccharide aid wound healing," *International Journal of Advanced Science and Technology*, vol. 28, no. 20, pp. 1130–1141, 2019.
- [31] P. Bassi and G. Kaur, "Polymeric films as a promising carrier for bioadhesive drug delivery: development, characterization and optimization," *Saudi Pharmaceutical Journal*, vol. 25, no. 1, pp. 32–43, 2017.
- [32] A. K. Shukla, R. S. Bishnoi, M. Kumar, V. Fenin, and C. P. Jain, "Applications of tamarind seeds polysaccharide-based copolymers in controlled drug delivery: an overview," *Asian Journal of Pharmacy and Pharmacology*, vol. 4, no. 1, pp. 23–30, 2018.
- [33] J. C. Dumville, P. Coulthard, H. V Worthington et al., "Tissue adhesives for closure of surgical incisions," *Cochrane Database of Systematic Reviews*, vol. 11, 2014.
- [34] I. Hwang, H. N. Kim, M. Seong et al., "Multifunctional smart skin adhesive patches for advanced health care," *Advanced Healthcare Materials*, vol. 7, no. 15, Article ID 1800275, 2018.
- [35] J. Chi, X. Zhang, C. Chen, C. Shao, Y. Zhao, and Y. Wang, "Antibacterial and angiogenic chitosan microneedle array patch for promoting wound healing," *Bioactive Materials*, vol. 5, no. 2, pp. 253–259, 2020.
- [36] Y. Wang, M. Guo, B. He, and B. Gao, "Intelligent patches for wound management: in situ sensing and treatment," *Analytical Chemistry*, vol. 93, no. 11, pp. 4687–4696, 2021.
- [37] M. Ochoa, R. Rahimi, J. Zhou et al., "Integrated sensing and delivery of oxygen for next-generation smart wound dressings," *Microsystems & Nanoengineering*, vol. 6, no. 1, pp. 1–16, 2020.
- [38] L. Liu, X. Li, M. Nagao, A. L. Elias, R. Narain, and H.-J. Chung, "A pH-Indicating colorimetric tough hydrogel patch towards applications in a substrate for smart wound dressings," *Polymers*, vol. 9, no. 11, p. 558, 2017.
- [39] R. B. Pothireddy, M. T. Mathai, and A. Julius, "Antibiotic free dehydrated human Amnionmembrane from C-section deliveries to accelerate wound healing," *International Journal of Advanced Science and Technology*, vol. 28, no. 20, pp. 212–217, 2019.